

Full Length Research Paper

Detection of *Helicobacter* DNA in Liver Tissues of Dogs with Indeterminate Hepatic Conditions

Marcasso R. A., Takemura L. S., Camargo P. L., Alfieri A. A. and Bracarense A. P. F. R. L.*

Laboratory of Animal Pathology, Department of Preventive Veterinary Medicine, Universidade Estadual de Londrina, Rodovia Celso Garcia Cid, Km 380, 86057-970, Londrina, PR, Brazil.

Received 28 April, 2024; Accepted December 11, 2024

Infection of the gastric mucosa by *Helicobacter* spp. is an important cause of gastric diseases and neoplasms in humans and animals. The objective of this study was to evaluate the presence of *Helicobacter* spp. in the livers of dogs with nonspecific histological changes. The association between *Helicobacter* spp. infection, hepatocyte proliferation and E-cadherin expression was also evaluated. Liver samples from 39 dogs were subjected to polymerase chain reaction (PCR) to identify *Helicobacter* spp. Hepatocyte proliferation was evaluated by the AgNOR method. The *Helicobacter* genus was detected in seven (17.9%) animals that exhibited liver histological changes. Twenty-six animals were PCR negative and exhibited microscopical changes, while six animals demonstrated no histological changes and were PCR negative. Infected animals showed a significant increase in liver lesional score and the area of NORs compared to non-infected dogs. E-cadherin expression showed no significant difference among groups. The results suggest that *Helicobacter* spp. and hepatocytes injury in the livers of dogs could contribute to increased cell proliferation, thereby influencing hepatocarcinogenesis.

Key words: Dog, helicobacter, liver, AgNOR, immunohistochemistry, E-cadherin.

INTRODUCTION

Helicobacter infection is considered an important cause of stomach disease and gastric neoplasia in humans (Buckley and O'Morain, 1998; Morgner et al., 2000). *Helicobacter pylori* is the main species that infects humans; its pathogenicity is attributed to factors that induce cell proliferation and apoptosis such as production of adhesins and cytotoxins (Blaser and Atherton, 2004; Galmiche et al., 2000). Thus, infection can cause disruption of the gastric mucosal barrier and induce the release of inflammatory mediators that enhance

apoptosis and cell turnover (Peek et al., 2010). Research on *Helicobacter* spp. has led to the discovery of other species in the gastric mucosa and other tissues (Fox et al., 2002; Germani et al., 1997; Huang et al., 2004). The presence of *Helicobacter hepaticus*, *Helicobacter bilis*, *Helicobacter canis*, "*Flexispira rappini*" and *Helicobacter pullorum* has been reported in the liver (Fox et al., 1996a, 1998) in association with cirrhosis in humans (Pellicano et al., 2008) and cholangitis and vasculitis in mice (Fox et al., 1996b). Previous studies in humans have suggested an

*Corresponding author. E-mail: ana.bracarense@pq.cnpq.br. Tel: 55 43 3371 4485. Fax: 55 43 3371 4714.

interaction between *Helicobacter* infection and the development of liver, biliary and pancreatic neoplasias (Huang et al., 2004; Ito et al., 2004; Mishra et al., 2010; Stalke et al., 2005; Takemura et al., 2009). This interaction has already been demonstrated in laboratory animals (Fox et al., 1996b; Huang et al., 2009); however the knowledge among natural occurrence and their consequences are rarely studied (Eaton et al., 1996; Fox et al., 1996b) and the pathogenic mechanisms remain poorly understood (Huang et al., 2009; Ito et al., 2004).

Primary hepatobiliary neoplasms are uncommon in dogs and cats (Liptak, 2007), while chronic hepatitis has a prevalence of 12% in dogs (Watson et al., 2010). Frequently, the diagnosis of the causes of hepatitis is not established, leading to a diagnosis of idiopathic hepatitis (Favier, 2009). *H. canis* was detected in the liver of a dog with multifocal necrotizing hepatitis initially classified as idiopathic (Fox et al., 1996a). The prevalence of natural chronic hepatitis in dogs may be a key to finding out the causes in idiopathic hepatitis, contributing to providing the right treatment, both in humans and animals. Thus, this study aimed to evaluate histological lesions and changes on cell proliferation and E-cadherin expression on livers of naturally *Helicobacter* spp. infected dogs.

MATERIALS AND METHODS

Samples

Thirty-nine dogs from a Veterinary Hospital that had died or been euthanized due to primary illness were selected. The causes of death of the dogs were diverse and included mainly non-liver neoplasia in advanced stages, paraneoplastic syndrome and traumatic injury. The selection process included only dogs that were necropsied within 30 min after death. The animals' medical records were examined later to identify the major clinical features. The animals were subjected to standard necropsy. The liver and gallbladder were removed for macroscopic analysis. Four samples from the liver and two from the gallbladder were collected from each animal. The gallbladder was incised at its axis, and fragments 0.5 cm² were collected from points equidistant from the gallbladder and the central region of the liver lobes. The two gallbladder samples and two of the liver samples were evaluated by polymerase chain reaction (PCR); the other two liver samples were subjected to histological analysis. Samples for PCR analysis were placed in RNase- and DNase-free microtubes and kept at -20°C until processing. The study was approved by the institutional Ethics Committee for Animal Experimentation (number 35786) and samples were collected with consent from the owners of the animals.

Polymerase chain reaction

For the molecular analysis, the samples of liver and gallbladder were subjected to enzymatic digestion, using 25 µl of proteinase K (20 µg/ml), and 200 µl of lysis buffer pH 8 (100 mM sodium chloride, 100 mM EDTA and 0.5% sodium dodecyl sulfate). The solution was vortexed and incubated in a 56°C water bath for 3 h. DNA was extracted from 500 µl of the material resulting from digestion according to the method established by Takemura et al. (2009). All the PCR reactions were prepared in a final volume of 25

µl, using 5 µl of DNA mix (1 µl of extracted DNA, 3.0 µl of water and 1 µl of each primer at 20 pM) and 20 µl of reaction mix containing 11.75 µl water, 0.4 mM each dNTP, 1x PCR buffer (20 mM Tris-HCl, pH 8.4 and 50 mM KCl), 1.25 U platinum Taq DNA polymerase and 1.5 mM MgCl₂ (InvitrogenTM Life Technologies, USA).

The sequences of the primers (Gibco, Brazil) used to detect *Helicobacter* spp. (16S rRNA gene) were (f) 5' AAC GAT GAA GCT TCT AGC TTG CTA 3' and (r) 5' CTT GTG ATT ATA GCC TCA CST NAG T 3', yielding an amplified product of 399 base pairs (Germani et al., 1997). The amplification reaction was performed in a thermocycler model PTC-100TM (MJ Research Inc.) as follows: initial denaturation at 95°C for 5 min, annealing at 65°C and extension at 72°C; the program was repeated for 40 one-minute cycles, with a final extension at 72°C for 10 min. Sterile ultrapure water was used as the negative control for DNA extraction. PCR products were analyzed by electrophoresis in 2.0% agarose gels with 0.3% ethidium bromide in a 10% Tris-Borate-EDTA buffer (TBE) and examination under UV light.

Histopathological analysis

The liver samples for the histological evaluation were fixed in 10% buffered formalin, embedded in paraffin and processed routinely. Sections (3 µm) were stained with haematoxylin and eosin (HE). Microscopic observation led to the identification of histological changes (congestion, trabecular disorganization, inflammatory cell infiltrate, hepatocyte degeneration and necrosis) and allowed for establishing an index of histological alterations (IHA) per animal. The IHA was calculated by taking into account the extension of each lesion (scored 1 to 4, where 1 was normal, 2 mild, 3 moderate and 4 extensive lesions) and the severity of the lesion (severity factor – 0 for congestion and trabecular disorganization, 10 for inflammatory infiltrate and hepatocyte degeneration and 100 for hepatocyte necrosis). The IHA was established for each animal using the following formula adapted from Grenier et al. (2011):

$$10^0 \Sigma \text{IHA} = (a + b) \Sigma + 10^1 (c + d) + 10^2 (e)$$

Where IHA = index of histological alterations, a = congestion, b = trabecular disorganization, c = inflammatory cells, d = degeneration of hepatocytes, e = necrosis. Thus, a total lesional score was established: 122 to 128 normal liver, 129 to 158 liver with mild alterations (159 to 188) liver with moderate alterations and (> 189) liver with severe alterations. The modified AgNOR method was used for analysis of cell proliferation (Crocker and Skilbeck, 1987). A quantitative evaluation was conducted by counting the number of nucleolar organiser regions (NORs) in 200 hepatocytes using a 100x objective (Aoki et al., 1994). A digital camera (Moticam 2.0) was used to capture images and MOTIC Images Plus 2.0 ML software was used to delineate the area of the NORs counted per nucleus.

Immunohistochemical assay

The expression of E-cadherin was used to assess inter-hepatocyte adhesion. Histological sections on previously silanised slides were deparaffinised and subjected to antigen retrieval. The slides subjected to anti-E-cadherin immunostaining were immersed in citrate buffer (pH 6.0) solution and heated in a water bath (98°C) for 15 min. Endogenous peroxidase was blocked using hydrogen peroxide (20 V). Sections were incubated with primary antibody anti-E-cadherin (clone 4A2C7, Zymed, California, CA, 1:50) overnight at 4°C. The samples were incubated with the secondary antibody (HRP polymer, Zymed, California, CA) and the staining was developed with 3,3'-diaminobenzidine substrate-chromogen solution (Zymed, California, CA), followed by counterstaining with

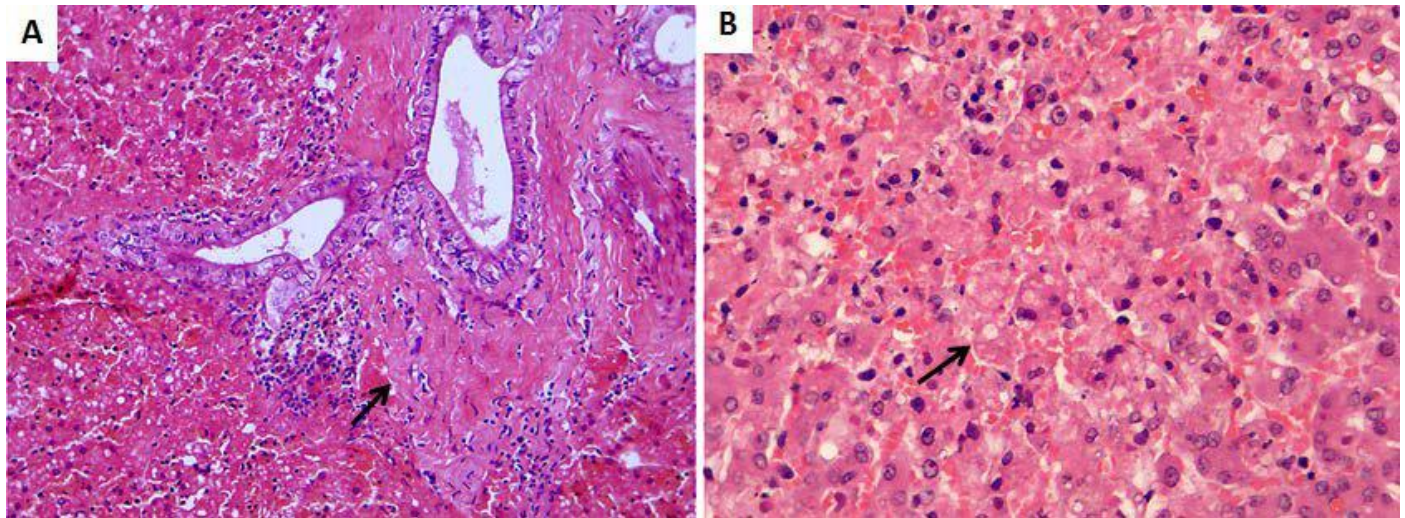


Figure 1. Liver, dog positive for *Helicobacter* spp. (group 2) . **(A)** Moderate periportal lymphocyte infiltrate and fibrosis (arrow). Hematoxylin and eosin (HE). Objective 20x. **(B)** Liver, dog negative for *Helicobacter* spp. and with hepatic changes (group 3). Mild vacuolar degeneration and focal necrosis (arrow). HE. Objective 40x.

Harris' haematoxylin solution. Positive and negative controls were used in all reactions according to the manufacturer's recommendations; the positive controls were squamous epithelium for E-cadherin. Each sample was assessed as showing either normal or reduced staining for E-cadherin. Normal staining was considered when a homogeneous and strong basolateral membrane staining of hepatocytes was detected. Heterogeneous and weak staining was considered to indicate reduced expression.

Statistical analysis

The Fisher exact test and Wilcoxon Mann-Whitney test were used to evaluate staining for anti-E-cadherin and to test the association with the presence of *Helicobacter* spp. The rate of histological changes was evaluated with the Student-Newman-Keuls test. To compare AgNOR numbers in dogs positive and negative with *Helicobacter* spp., analysis of variance (ANOVA) was used with a statistical significance of 5%.

RESULTS

Polymerase chain reaction

Samples of seven animals (7/39) were positive for *Helicobacter* spp. by PCR. Among the dogs testing positive, four samples were taken from the liver, one from the gallbladder and two from both tissues. None of the PCR positive samples were from dogs presenting clinical signs of hepatic disease.

Microscopical features

The 39 liver samples stained with HE were analyzed and graded according to the lesion-scoring system. Six

samples were classified as normal, while the others had some degree of alteration. Samples considered normal were also negative by PCR (n = 6), and they were used as the control group (G1). Among the animals with liver lesions, seven were positive by PCR and formed Group 2 (G2). The other 26 animals were negative by PCR and showed histological alterations to varying degrees; these animals formed Group 3 (G3). In Group 1 the main histological change was mild congestion (4/6). The main findings observed in G2 were moderate congestion (4/7), trabecular disorganization (6/7), vacuolar degeneration of hepatocytes (4/7), mild to moderate lymphocyte periportal infiltration (6/7) (Figure 1A) and focal necrosis (2/7) . The most frequent histological changes observed in G3 were inflammatory infiltrate (24/26), trabecular disorganization (22/26) and vacuolar degeneration (21/26). Multifocal necrosis occurred in 11/26 samples (Figure 1B). A significant increase in histological changes was observed in G2 and G3 compared to G1. The index of histological alterations in all groups is shown in Figure 2.

Histochemical and immunohistochemical assay

NOR morphology was used to assess hepatocyte proliferation. A significant reduction in the number of NORs was verified in dogs presenting hepatic histological changes compared to the control group. On the other hand, animals positive for *Helicobacter* spp. showed significant increased values for NOR dot area and NOR area per cell (Table 1). The results for all groups are presented in Table 1. The assessment of hepatocyte adhesion was performed using E-cadherin expression. A reduced expression of the protein was observed in

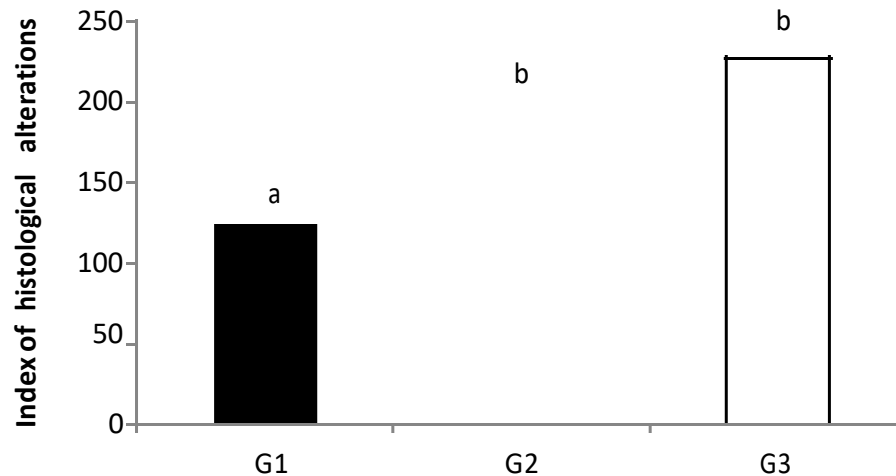


Figure 2. Index of histological alterations (IAH) in dogs. G1 (IAH = 123.5); G2 (IAH= 193.4); G3 (IAH = 227.2). Student-Newman-Keuls test: different letters, statistical significance: G1×G2: p=0.0210; G1×G3: p<0.0001; G2×G3: p=0.2042. G1 = negative group and no histological alterations, G2 = positive group and histological alterations; G3 = negative group and histological alterations.

Table 1. Mean AgNOR number per cell, mean size of individual AgNOR dots and mean entire AgNOR hepatocyte in infected and uninfected samples.

Parameter	Mean values (± SD) of cell proliferation		
	G1 (n=6)	G2 (n=7)	G3(n=26)
Number of NORs	1.54 ± 0.75 ^a	1.47 ± 0.70 ^b	1.27 ± 0.57 ^c
NOR dot area	2.05 ± 1.02 ^a	2.36 ± 1.33 ^b	2.17 ± 1.17 ^c
NOR area/cell	2.23 ± 0.93 ^a	2.56 ± 1.30 ^b	2.32 ± 1.112 ^c

SD- standard deviation. ANOVA test: different letters on the same line, statistical significance with p≤0.05.

infected animals, however there was no significant difference among the groups (p > 0.05) (Figure 3).

DISCUSSION

The association between *Helicobacter* species DNA in liver and liver diseases such as cirrhosis and hepatocellular carcinoma has led to the hypothesis that these bacteria may play a role in the evolution of hepatic lesions (Rocha et al., 2005). In this study, *Helicobacter*-positive PCRs were obtained from the livers and gallbladders of dogs with histological changes. In contrast to the high occurrence (91 to 94.6%) of *Helicobacter* spp. observed in the gastric mucosa of dogs and cats (Eaton et al., 1996), an occurrence of 18% was observed in liver samples. There are no data on the frequency of liver or biliary infection with *Helicobacter* spp. in pets, as such reports are scarce (Fox et al., 1996a, 2002). However, in a retrospective study in humans, *Helicobacter* was found in 4.2% of control patients, 3.5% of patients with non-

cirrhotic hepatitis C, 68% of cirrhotic patients with hepatitis C and 61% of patients with hepatocellular carcinoma (Rocha et al., 2005). We can hypothesize that dogs presenting cirrhosis or hepatic neoplasms could exhibit a greater occurrence of infection.

Aside from determining the occurrence of *Helicobacter* spp. in the liver and gallbladder of dogs, this study aimed to evaluate the relationship between the presence of these bacteria and microscopic liver alterations. It was surprising that the majority of dogs presented no clinical signs of hepatic diseases (84.6%); however they exhibited liver histological changes. In the positive dogs, liver lesions were observed, including lymphocyte infiltrate, hepatocyte degeneration and necrosis; however, the rate of histological alterations did not differ between the group with liver lesions and *Helicobacter*-positive PCRs and those with negative PCRs. It seems that histological characteristics of hepatic injury are too general and there is no particular histologic lesion in the *Helicobacter*-positive PCR samples. We have not performed other bacteriological or virological tests;

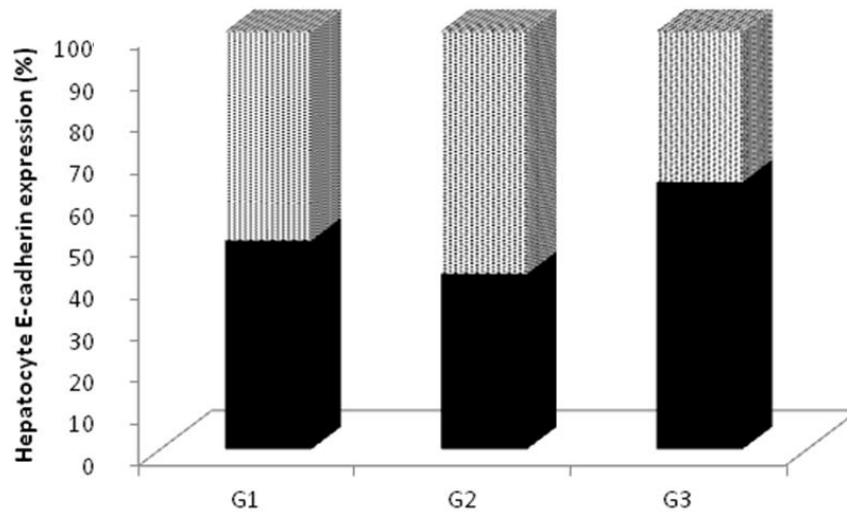


Figure 3. Percentage (%) of animals showing weak and heterogeneous (▨), and strong and homogeneous (■) E-cadherin expression. G1 = negative group and no histological alterations, G2 = positive group and histological alterations; G3 = negative group and histological alterations. Fisher test: G1×G2 ($p=1.00$); G1×G3 ($p=0.64$); G2×G3 ($p=0.39$).

however canine adenovirus and herpesvirus can be diagnosed by viral inclusions observed on histological slides (Myers et al., 2011) that were not observed in our samples. Although the evidence is not sufficient to affirm that *Helicobacter* spp. was the causative agent of injury, studies have reported lesions in infected animals. Multifocal necrotizing hepatitis was reported in a dog infected with *H. canis* (Fox et al., 1996a) and in woodchucks infected by *H. marmotae* sp. nov. (Fox et al., 2002). In mice, inoculation of *H. hepaticus* and *H. bilis* induced cholangitis and vasculitis, which progressed to biliary hyperplasia, round cell hyperplasia, hepatocellular proliferation and hepatoma (Fox et al., 1996b).

The association between infection of the liver by *Helicobacter* spp. and the induction of cirrhosis or liver cancer has been demonstrated in several studies (Huang et al., 2004; Mishra et al., 2010; Rocha et al., 2005). Alterations in cell proliferation in the gastric mucosa have been observed in humans (De Freitas et al., 2004) and animals infected with *Helicobacter* spp. (Bracarense et al., 2013; Takemura et al., 2009). In this study, we also aimed to evaluate the association between *Helicobacter* infection and hepatocyte proliferation and E-cadherin expression. A significant increase in hepatocyte proliferation was observed in dogs with histological liver changes compared to the control group. Despite both groups with histological changes exhibited increased AgNOR area, in positive samples the increase was significantly higher. The histochemical method revealed significantly increased AgNOR area in the positive dogs, indicating that they had higher levels of transcriptional activity in the hepatocytes than did negative dogs.

Increased cell proliferation in the presence of *H. pylori*

is related to the production of cytotoxins such as CagA and induction of cellular inflammatory mediators that enhance cell renewal (Peek et al., 2010). Thus, the increased cellular replication in dogs with positive PCR results suggests that *Helicobacter* spp. may be involved in maintaining a chronically inflammatory environment that intensifies the transcriptional process and may influence hepatocarcinogenesis.

Cadherins are proteins that participate in cellular adhesion for communication between cells (for example, for signaling and cellular differentiation) (Simecková et al., 2009). In this study, no difference in the expression of E-cadherin was observed between dogs with positive and negative PCR results. A decrease in the expression of cadherins has been linked to the growth of neoplasias with greater potential for invasion and metastasis (Guo et al., 2008). An *in vitro* study demonstrated that infection with CagA(+) *H. pylori* induces changes in the expression of E-cadherin and β -catenin stimulating apoptosis and compensatory cell proliferation and thus facilitating the acquisition of mutations in gastric epithelial cells (Murata-Kamiya et al., 2007). Most likely, these liver lesions were not sufficiently severe to induce changes in E-cadherin expression.

Vakkila and Lotze (2004) have presented data on the multiplicity of mechanisms and pathways in chronic infections that may contribute to carcinogenesis. *Helicobacter* spp. infection is a risk factor for cirrhosis and hepatobiliary carcinoma, particularly in humans infected with hepatitis C virus (Rocha et al., 2005). In this study, we observed that dogs positive for *Helicobacter* spp. showed histological changes. The differences in the severity of the lesions could be due to multiple factors

such as time of infection, pathogenic variations among the infecting species or the absence of concomitant infective agents that promote synergistic effects.

Little is known about the main *Helicobacter* species that infect the liver mainly as a result of difficulty in isolating and cultivating these microorganisms (Pellicano et al., 2008). As a result, it is still uncertain whether the agent detected by molecular biology is responsible for the observed liver alterations. Therefore, even today most primary hepatitis is regarded as idiopathic (Favier, 2009).

In conclusion, this study detected the presence of genetic material from *Helicobacter* spp. in the livers of dogs with histological changes. A significant association was observed between the presence of the bacteria and increased liver histological changes and hepatocyte proliferation. These results suggest that *Helicobacter* spp. should be considered among the causes of liver disease in dogs.

Conflict of Interests

The authors have not declared any conflict of interests.

ACKNOWLEDGEMENT

R. A. M. was supported by a master fellowship financed by CNPq, Brazil. This study was supported by a grant from Fundação Araucária, Brazil.

REFERENCES

- Aoki K, Sakamoto M, Hirohashi S (1994). Nucleolar organizer regions in small nodular lesions representative early stages of human hepatocarcinogenesis. *Cancer* 73(2):289-293.
- Blaser MJ, Atherton JC (2004). *Helicobacter pylori* persistence: Biology and disease. *J. Clin. Invest.* 113(3):321-333.
- Bracarense APFRL, Yamasaki L, Silva EO, Oliveira RL, Alfieri AA (2013). *Helicobacter* spp. infection induces changes in epithelial proliferation and E-cadherin expression in the gastric mucosa of pigs. *J. Comp. Pathol.* 149:402-409.
- Buckley MJM, O'Morain CA (1998). *Helicobacter* biology – discovery. *Br. Med. Bull.* 54(1):7-16.
- Crocker J, Skilbeck N (1987). Nucleolar organizer region associated proteins in cutaneous melanotic lesions: A quantitative study. *J. Clin. Pathol.* 40(8):885-889.
- De Freitas D, Urbano M, Goulao MH, Donato MM, Baldaia C, Martins MI, Souto P, Gregorio C, Figueiredo P, Gouveia H, Romãozinho JM (2004). The effect of *Helicobacter pylori* infection on apoptosis 294 and cell proliferation in gastric epithelium. *Hepato-gastroenterology* 51(57):876-882.
- Eaton KA, Dewhirst FE, Paster BJ, Tzellas N, Coleman BE, Paola J, Sherding R (1996). Prevalence and varieties of *Helicobacter* species in dogs from random sources and pet dogs: animal and public health implications. *J. Clin. Microbiol.* 34(12):3165-3170.
- Favier RP (2009). Idiopathic hepatitis and cirrhosis in dogs. *Vet. Clin. North. Am. Small Anim. Pract.* 39(3):481-488.
- Fox JG, Dewhirst FE, Shen Z, Feng Y, Taylor NS, Paster BJ, Ericson RL, Lau CN, Correa P, Araya JC, Roa I (1998). Hepatic *Helicobacter* species identified in bile and gallbladder tissue from Chileans with chronic cholecystitis. *Gastroenterology* 114(4):755-763.
- Fox JG, Drolet R, Higgins R, Messier S, Yan L, Coleman BE, Paster BJ, Dewhirst FE (1996a). *Helicobacter canis* isolated from a dog liver with multifocal necrotizing hepatitis. *J. Clin. Microbiol.* 34(10):2479-2482.
- Fox JG, Li X, Yan L, Cahill RJ, Hurley R, Lewis R, Murphy JC (1996b). Chronic proliferative hepatitis in A/JCr mice associated with persistent *Helicobacter hepaticus* infection: A model of *Helicobacter*-induced carcinogenesis. *Infect. Immun.* 64(5):1548-1558.
- Fox JG, Shen Z, Xu S, Feng Y, Dangles CA, Derwhirst FE, Paster BJ, Cullen JM (2002). *Helicobacter marmotae* sp. nov. isolated from livers of woodchucks and intestines of cats. *J. Clin. Microbiol.* 40(7):2513-2519.
- Galmiche A, Rassow J, Doye A, Cagnol S, Chambard JC, Contamin S, de Thillot V, Just I, Ricci V, Solcia E, Van Obberghen E, Boquet P (2000). The N terminal 34 kDa fragment of *Helicobacter pylori* vacuolating cytotoxin targets mitochondria and induces cytochrome c release. *EMBO J.* 19(23):6361-6370.
- Germani Y, Dauga C, Duval P, Huerre M, Levy M, Pialoux G, Sansonetti P, Grimont PA (1997). Strategy for the detection of *Helicobacter* species by amplification of 16S rRNA genes and identification of *H. felis* in a human gastric biopsy. *Res. Microbiol.* 148(4):315-326.
- Grenier B, Bracarense APFRL, Lucioi J, Pacheco GD, Cossalter AM, Moll WD, Schatzmayr G, Oswald IP (2011). Individual and combined effects of subclinical doses of deoxynivalenol and fumonisins in piglets. *Mol. Nutr. Food Res.* 55(5):761-771.
- Guo C, Liu QG, Yang W, Zhang ZL, Yao YM (2008). Relation among p130Cas, E-cadherin and beta-catenin expression, clinicopathologic significance and prognosis in human hepatocellular carcinoma. *Hepatobiliary Pancreat. Dis. Int.* 7(5):490-496.
- Huang Y, Fan XG, Wang ZM, Zhou JH, Tian XF, Li N (2004). Identification of *Helicobacter* species in human liver samples from patients with primary hepatocellular carcinoma. *J. Clin. Pathol.* 57(12):1273-1277.
- Huang Y, Tian XF, Fan XG, Fu CY, Zhu C (2009). The pathological effect of *Helicobacter pylori* infection on liver tissues in mice. *Clin. Microbiol. Infect.* 15(4):843-849.
- Ito K, Nakamura M, Toda G, Negishi M, Torii A, Ohno T (2004). Potential role of *Helicobacter pylori* in hepatocarcinogenesis. *Int. J. Mol. Med.* 13(2):221-227.
- Liptak JM (2007). Hepatobiliary tumors. In: Whitrow SJ, Vail DM. ed. *Small Animal Clinical Oncology*. 4th ed. St Louis, Missouri, USA: Saunders Elsevier: pp. 483-491.
- Mishra RR, Tewari M, Shukla HS (2010). *Helicobacter* 344 species and pathogenesis of gallbladder cancer. *Hepatobiliary Pancreat. Dis. Int.* 9(2):129-134.
- Morgner A, Lehn N, Andersen LP, Thiede C, Bennedsen M, Trebesius K, Neubauer B, Neubauer A, Stolte M, Bayerdörffer E (2000). *Helicobacter heilmannii* -associated primary gastric low-grade MALT lymphoma: Complete remission after curing the infection. *Gastroenterology* 118(5):821-828.
- Murata-Kamiya N, Kurashima Y, Teishikata Y, Yamahashi Y, Saito Y, Higashu H, Aburatani H, Akiyama T, Peek RM Jr, Azuma T, Hatakeyama M (2007). *Helicobacter pylori* CagA interacts with E-cadherin and deregulates the beta-catenin signal that promotes intestinal trans differentiation in gastric epithelial cells. *Oncogene* 26(32):4617-4626.
- Myers RK, McGavin MD, Zachary JF (2011). Cellular Adaptations, Injury, and Death: Morphologic Biomechanical, and Genetic Bases. In: Zachary JF, McGavin MD, ed. *Pathologic Basis of Veterinary Disease*. 5th ed. St Louis, Missouri, USA: Mosby Press: pp. 2-59.
- Peek RM Jr, Fiske C, Wilson KT (2010). Role of innate immunity in *Helicobacter pylori*-induced gastric malignancy. *Physiol. Rev.* 90(3):831-858.
- Pellicano R, Ménard A, Rizzetto M, Mégraud F (2008). *Helicobacter* species and liver diseases: association or causation? *Lancet. Infect. Dis.* 8(4):254-260.
- Rocha M, Avenaud P, Ménard A, Le Bail B, Balabaud C, Bioulac-Sage P, de Magalhães Queiroz DM, Mégraud F (2005). Association of *Helicobacter* species with hepatitis C cirrhosis with or without hepatocellular carcinoma. *Gut* 54(3):396-401.
- Simecková P, Vondráček J, Procházková J, Kozubík A, Krčmár P, Machala M (2009). 2,2',4,4',5,5'-hexachlorobiphenyl (PCB 153) induces degradation of adherens junction proteins and inhibits beta-

- catenin-dependent transcription in liver epithelial cells. *Toxicology* 260(1-3):104-111.
- Stalke P, Al-Soud WA, Bielawski KP, Bakowska A, Trocha H, Stepinski J, Wadström T (2005). Detection of *Helicobacter* species in liver and stomach tissues of patients with chronic liver diseases using polymerase chain reaction-denaturing gradient gel electrophoresis and immunohistochemistry. *Scand. J. Gastroenterol.* 40(9):1032-1041.
- Takemura LS, Camargo PL, Alfieri AA, Bracarense APFRL (2009). *Helicobacter* spp. in cats: association between infecting species and epithelial proliferation within the gastric lamina propria. *J. Comp. Pathol.* 141(2-3):127-134.
- Vakkila J, Lotze MT (2004). Inflammation and necrosis promote tumour growth. *Nat. Rev. Immunol.* 4(8):641-648.
- Watson PJ, Roulois AJ, Scase TJ, Irvine R, Herrtage ME (2010). Prevalence of hepatic lesions at post-mortem examination in dogs and association with pancreatitis. *J. Small Anim. Pract.* 51(11):566-572.