

Review

A Rare Case of Prostate Cancer Complicated by Schistosomiasis: Clinical Findings and Literature Review

Agabus N. Manasseh*, Godwins O. Echejoh, Matthew N. Tanko, Olugbenga O. Silas, Nuhu K. Dakum and Barnabas M. Mandong

Departments of Anatomical Pathology and Surgery, Jos University Teaching Hospital, Jos. Nigeria.

Accepted 25 February, 2025

Adenocarcinoma of the prostate is the commonest form of cancer in men and the second leading cause of cancer death. Not much is known about the aetiology of prostatic cancer. We report a rare case of prostatic adenocarcinoma coexisting with schistosomiasis of the prostate, and review of literature. The association between schistosomiasis and cancer has been well documented in bladder cancer, implicating the genotoxic effect of chronic inflammatory process from the generation of reactive oxygen species (ROS) and the nitrosating action of bacterial infection. There are no data yet proving the association of this disease with prostate neoplasia. The theory of the genotoxic effect of chronic inflammatory process may explain a “cause and effect” association between prostate cancer and schistosomiasis. A pertinent question therefore is, does schistosomiasis cause tumorigenesis in all tissues affected? This is the first record of prostatic schistosomiasis in association with prostatic cancer in our centre.

Key words: Tropical disease, parasite, carcinoma, prostate.

INTRODUCTION

Adenocarcinoma of the prostate is the commonest form of cancer in men and the second leading cause of cancer death according to American Cancer Society (2004). Histologically, most lesions are adenocarcinomas that produce well defined, readily demonstrable gland pattern (Epstein, 1995, 2002; Young et al., 2000). Prostatic cancer may show squamous differentiation resulting in either adenosquamous or pure squamous carcinoma (Little et al., 1993). Not much is known about the aetiology of prostatic cancer. However, several risk factors such as age, race, family history, hormone levels and environmental influences are suspected of playing roles (Gronberg, 2003; Nelson et al., 2003; Yip et al., 1999; Boyle et al., 2003). Of the environmental factors, no direct link to infectious agents has been documented.

Several studies have reported schistosomiasis of the prostate gland. Gelfand et al. (1970) documented the finding of schistosome eggs in 20% of 200 cadavers in their study. In another study by Vilana et al. (1997), schistosomal eggs were found in 50% of postmortem studies of prostate and seminal vesicles in endemic areas.

The association between schistosomiasis and cancer has been well documented in bladder cancer, however, there are no data yet proving the association of this disease with prostate neoplasia (Bacelar et al., 2007). Basilio-De-Oliveira et al. (2002) reported a case of coexistence of prostatic adenocarcinoma and schistosomiasis which they said was the fifth reported in literature, while Bacelar et al. (2007) reported a similar case which they said was the third reported in literature. In all the reported cases, no cause and effect association was known. This is the first time we are seeing prostatic schistosomiasis in association with prostatic cancer in our centre.

Case presentation

AM is a 70-year-old man who presented in the surgical outpatient clinic of our teaching hospital in June 2008 with a 3-month history of features of prostatism. There was no history of diabetes, sexually transmitted infection or trauma. On examination, his vital signs were essentially normal. Direct rectal examination showed a moderately enlarged prostate with smooth surface and mild tenderness. His serum prostatic specific antigen (PSA) was

*Corresponding author. E-mail: ogechejoh@yahoo.com.

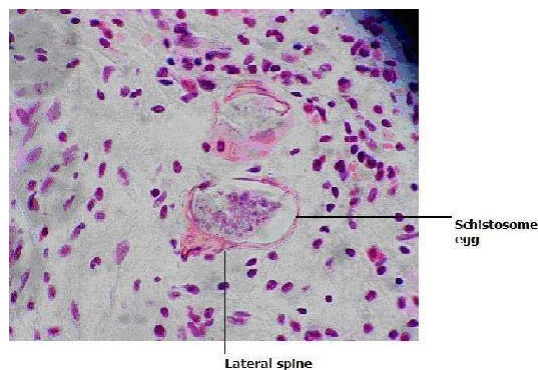


Figure 1. Shows two viable ova of *S. mansoni* with lateral spine in the lower ovum. Epithelioid cells, eosinophils, lymphocytes and plasma cells are seen surrounding the ova. Haematoxylin and eosin (H and E) stains. 40X objective.

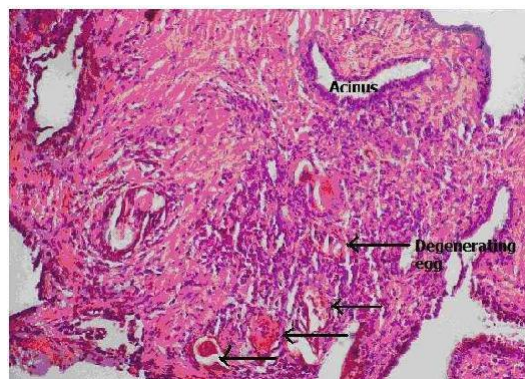


Figure 2. Showing some degenerating ova (arrows) with aggregates of mixed inflammatory cells. Several benign acini lined by columnar epithelium are present in this field. (H and E) stains. 20X objective.

17.11 ng/mL, which is high for age/assumed prostatic volume. A working diagnosis of nodular hyperplasia was made to rule out malignancy. After some preliminary laboratory tests were done to establish the patient's haematological and renal function status which were essentially normal, a tru cut biopsy of the prostate was done using the trans-rectal approach. Three cores of grayish white specimen were obtained and sent to the histopathology laboratory.

Gross and microscopic findings

At the cut-up bench of the histopathology laboratory, we found 3 cores of grayish white tissue preserved in 10% formal saline. These were subjected to routine tissue processing procedures. Five micron (5) thick sections were obtained from the paraffin wax embedded tissue and then stained with haematoxylin and eosin (H and E) stains.

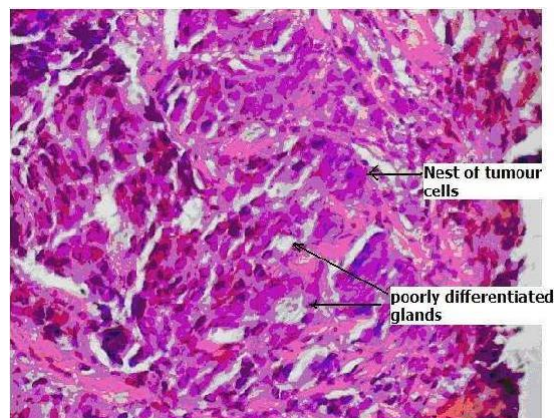


Figure 3. This field Shows nests of hyperchromatic neoplastic cells with some forming poorly differentiated glands. (H and E) stains. 20X objective.

Histology showed several ova of *Schistosoma mansoni* having lateral spine surrounded by aggregates of epithelioid cells, eosinophils, lymphocytes, and some plasma cells. Some poorly differentiated neoplastic glands in addition to nests of pleomorphic and hyperchromatic epithelial cells were also seen in the fibromuscular stroma (Figures 1, 2, and 3).

DISCUSSION AND REVIEW OF LITERATURE

In endemic geographical areas schistosomiasis has been implicated as an aetiological agent in the pathogenesis of bladder, colorectal and renal carcinoma (Ronald et al., 1995). In particular bladder carcinoma commonly occurs in such geographical location almost two decades earlier than in non-endemic areas (Ronald et al., 1995). Schistosome-related tumours are largely squamous cell carcinomas, but transitional cell carcinomas and adenocarcinomas of the bladder have also been reported (El-Bolkainy et al., 1972, 1981). Most studies of the pathology of schistosomiasis especially in association with tumours have been mainly on bladder lesions.

Schistosomes express numerous glycoconjugates with terminal LacNAc or LacdiNAc, (both soluble egg anti-gens) that provoke humoral and cellular immune responses in the infected human host. The main pathology is due to the formation of granulomas around tissue-trapped eggs and the resulting organ damage (Koen et al., 2006). One of the hallmark activities of tumour promotion in animals is their ability to recruit inflammatory cells to an application site and stimulate a respiratory burst in these cells. The cells release reactive oxygen species (ROS) such as superoxide anion and hydrogen peroxide, as well as lipid oxidation products (Harris et al., 1992; Gordon et al., 1988). This activity may be critical to tumour promotion. There is a strong concordance between the capacity of tumour promoters to stimulate inflammatory cells to release ROS and their capacity to promote tumours

(Frenkel, 1992). Further more, blocking the respiratory burst in animal models with agents such as retinoids, steroids, or antioxidants leads to the inhibition of tumour promotion. There is accumulating evidence that stimulated inflammatory cells are capable of inducing genotoxic effects, such as DNA strand breaks (Bimboim, 1982; Shacter et al., 1988) sister chromatid exchanges (Weitzberg, 1989), and mutation (Weitzman et al., 1984; Yamashina et al., 1986) and of promoting neoplastic transformation (Zimmerman et al., 1986; Weitzman et al., 1985) in nearby cells. Inflammatory cells have been shown to participate in the metabolic activation of procarcinogens to DNA-damaging species (Kensler et al., 1992; O'Brien, 1988; Trush et al., 1990). Neutrophils activate aromatic amines, aflatoxins, oestrogens, phenols and polycyclic aromatic hydrocarbons by oxidant dependent mechanisms (Kensler et al., 1992). Inflammatory cells are also implicated in the formation of carcinogenic nitrosamines (Marietta, 1988). Since the aromatic amines are an important group of bladder carcinogens, an increased number of inflammatory cells in the urinary bladder of schistosomal patients may enhance the carcinogenic potential of these agents by increasing their rate of activation. Various strains of bacteria have been identified in the livers of animals (Ottens et al., 1972), in human gastric juice (Massoud et al., 1990), and urine (El-Hawey et al., 1989; Mostafa et al., 1994) in association with schistosome infection. Some of these organisms are thought to play a significant role in the endogenous formation of *N*-nitrosamines. Nitrate-reducing bacteria, including *Staphylococcus aureus*, hemolytic *Staphylococcus albus*, *Proteus mirabilis*, *Klebsiella* spp., and *E. coli* (Hicks et al., 1982) were isolated from the urine of *S. haematobium*-infected patients. Several of these organisms can mediate nitrosation reactions *in vitro* between secondary amines and nitrate under the conditions of physiological pH normally encountered in the urinary bladder (Calmels et al., 1986). A correlation between schistosomiasis and bacterial infection of the urinary tract thus provides supporting evidence for the endogenous formation of *N*-nitroso compounds and the possible consequent induction of preneoplastic initiating events in schistosome-infected subjects. Bacterial infection of the urinary tract per se has been reported to increase the risk of bladder cancer in patients with associated with advanced disease and tumor recurrence (Coombs et al., 1991). and *c-myc*, leading to more aggressive and invasive tumor properties (Kroft et al., 1994). Overexpression of *c*-chronic or repeated cystitis (Kantor et al., 1984; Radomski et al., 1978), paraplegia (Melzak, 1966), or *S. haematobium* infection (Hicks et al., 1976), as well as to increase the risk of all cancers (Nordenstam et al., 1986). The mechanisms of initiation of these and many different types of cancer could be due to the nitrosation of secondary amines with ingested or metabolically derived nitrite that leads to *N*-nitrosamine formation (Hill, 1988).

Miriam et al. (1994) in their study using the exfoliated

cell micronucleus test reported that individuals with urinary bladder schistosomiasis have elevated levels of genomic damage in their bladders, and that treatment that kills the parasite also reduces the micronucleus frequencies (Miriam et al., 1994). Micronuclei are formed by damage to chromosomes or to the spindle apparatus in the basal cells of the tissue epithelium. When these cells divide, chromosomal fragments (or entire chromosomes lacking an attachment to the spindle apparatus) lag behind and are excluded from the main nuclei in the daughter cells. These fragments form their own membranes and appear as Feulgen-positive bodies in the cytoplasm of the daughter cells which mature and are exfoliated into urine (Miriam et al., 1994).

Several studies have shown the possible loci on some chromosomes affected in schistosome-related tumours. Miriam et al. (1994) suspected involvement of certain loci on chromosome 11 responsible for DNA repair process as reported in earlier study by Parshad et al. (1992). Miriam et al. (1994) then found out that insertion of a normal chromosome 11 by microcell-mediated transfer led to lowering of micronucleus frequencies in the exfoliated cells from schistosome infected individuals (Miriam et al., 1994).

Recent other studies have attempted to identify molecular events associated with specific genes that underlie neoplastic progression in the development of schistosomal bladder cancer. These include the activation of *H-ras* (Knowles et al., 1993), inactivation of *p53* located on chromosome 17 (Sidransky et al., 1991), and inactivation of the retinoblastoma gene (Ishikawa et al., 1991). For Egyptian schistosomiasis-associated bladder cancers (Habuchi et al., 1993), it was reported that about 86% (six of seven) of these had *p53* mutations in exons 5, 6, 8, and 10 and that in a Japanese group (61 patients) the mutation frequency increased with the tumor grade. These findings are in agreement with a literature based observation that the frequency of *p53* mutations varies with the different grades of schistosomiasis-associated bladder cancer (Badawi, 1996). Thus, *p53* inactivation ranged from 0 to 38% at the early stage of the disease, as opposed to 33 to 86% in the advanced tumor stage (Badawi, 1996). Experimental studies on *ras* mutations *in vitro* have also shown a cumulative effect with other genetic alterations, including those of *c-erbB-2* *erb-B-2* in transitional cell carcinoma (TCC) has been Allelic loss of chromosome 9 was also observed in both superficial and invasive bladder cancers (Miyao et al., 1993). Recently, Warren et al. (1995) found that 30 of 90 Egyptian patients with a history of schistosomiasis had tumors with mutations in exons 5 through 8 of the *p53* gene: 17 of 53 of these mutations were in squamous cell carcinoma (SCC), 8 of 23 were in TCC, 4 of 13 were in adenocarcinoma and 1 of 3 was in other tumors.

Changes in cell cycle control are thought to be critically associated with cancer development (Nurse, 1997). In fact, cyclin D1 is over-expressed in some cancers, includ-

ing bladder cancer (Tamimi et al., 1996). Seven CDK inhibitors, including p57, p21, p27, p19, p18, p16/*INK4*, and p15, have been characterized. Tamini et al. (1996) found that a p16/*INK4* deletion was present in 23 of 47 samples from schistosomiasis associated bladder cancer patients and that mutations were present in another 2 patients (in all, 53% of tumors exhibited p16/*INK4* gene alterations). They concluded that p16/*INK4* alterations are more frequent in schistosomiasis-associated bladder cancer than in other bladder tumors and may thus be associated with a specific etiology (Tamimi et al., 1996).

Conclusion

These elaborate studies of the association between bladder tumours and schistosomiasis have not been done in schistosome associated prostate cancer probably because of its rarity. However, the genotoxic effect of chronic inflammatory process from the generation of ROS and the nitrosating action of associated bacterial infection may be a genuine explanation to "cause and effect" association between prostate cancer and schistosomiasis. A pertinent question therefore is, does schistosomiasis cause tumorigenesis in all organs or tissues affected, and does this follow a metaplastic change or outright transformation of native parenchymal/epithelial cells? This can only be found out by such dedicated fact finding studies as have been done in the case of schistosome associated bladder cancer.

REFERENCES

- American Cancer Society (2004). Cancer Facts and Figures. Atlanta, GA: American Cancer Society.
- Bacelar A, Castro LG, de Queiroz AC, Café E (2007). Association between prostate cancer and schistosomiasis in young patients: a case report and literature review. *Braz J Infect Dis*. 11(5):520-522.
- Badawi AF (1996). Molecular and genetic events in schistosomiasis associated human bladder cancer: role of oncogenes and tumor suppressor genes. *Cancer Lett*. 105:123-138.
- Basilio-De-Oliveira CA, Aquino A, Simon EF, Eyer-Silva WA (2002). Concomitant prostatic schistosomiasis and adenocarcinoma: case report and review. *Br. J. Infect. Dis*. 6(1):45-49.
- Birnboim HC (1982). DNA strand breakage in human leukocytes exposed to a tumor promoter, phorbol myristate acetate. *Science (Washington DC)*. 215:1247-1249.
- Boyle P, Severi G, Giles GG (2003). The epidemiology of prostate cancer. *Urol. Clin. North Am*. 30:209.
- Calmels S, Ohshima H, Bartsch H (1988). Nitrosamine formation by denitrifying and non-denitrifying bacteria: implication of nitrite reductase and nitrate reductase in nitrosamine analysis. *J. Gen. Microbiol*. 134:221-226.
- Coombs LM, Pigott DA, Sweeney E (1991). Amplification and over-expression of *c-erbB-2* in transitional cell carcinoma of the urinary bladder. *Br. J. Cancer*. 63:601-608.
- El-Bolkainy MN, Ghoneim MA, Mansour MA (1972). Carcinoma of the bilharzial bladder in Egypt: clinical and pathological features. *Br. J. Urol*. 44:561-570.
- El-Bolkainy MN, Mokhtar NM, Ghoneim MA, Hussein MH (1981). The impact of schistosomiasis on the pathology of bladder carcinoma. *Cancer*. 48:2643-2648.
- El-Hawey A, Massoud A, Badr D, Waheeb A, Abdel-Hamid S (1989). Bacterial flora in hepatic encephalopathy in bilharzial and non-bilharzial patients. *J. Egypt. Soc. Parasitol*. 19:797-804.
- Epstein JI (1995). Diagnostic criteria of limited adenocarcinoma of the prostate on needle biopsy. *Hum Pathol*. 26:223.
- Epstein JI (2002). Interpretation of Prostate Biopsies, 3rd ed. Philadelphia, Lippincott Williams and Wilkins.
- Frenkel K (1992). Carcinogen-mediated oxidant formation and oxidative DNA damage. *Pharmacol. Ther*. 53: 127-166.
- Gelfand M, Ross CMD, Blair DM, Castle WM, Weber MC (1970). Schistosomiasis of the male pelvic organs: severity of infection as determined by Digestion of Tissue and Histologic Methods in 300 Cadavers. *Am. Trop. Med. Hyg*. 19(5):779-784.
- Gordon LI, Weitzman SA (1988). The respiratory burst and carcinogenesis. In: AJ Sbarra and RR Strauss (eds.), *The Respiratory Burst and Its Physiological Significance*. New York: Plenum Press, pp. 277-298.
- Gronberg H. Prostate cancer epidemiology (2003). *Lancet*. 361:859.
- Habuchi T, Takahashi R, Yamada H (1993). Influence of cigarette smoking and schistosomiasis on p53 gene mutation in urothelial cancer. *Cancer Res*. 53:3795-3799.
- Harris ML, Schiller HJ, Reilly PM, Donowitz M, Grisham MB, Bulkley GB (1992). Free radicals and other reactive oxygen metabolites in inflammatory bowel disease: cause, consequence or epiphenomenon. *Pharmacol. Ther*. 53: 375-408.
- Hicks RM, Ismail MM, Walters CL, Beecham PT, Rabie MT, El-Alamy MA (1982). Association of bacteriuria and urinary nitrosamine formation with *Schistosomiasis haematobium* infection in the Qalyub area of Egypt. *Trans. R. Soc. Trop. Med. Hyg*. 76:519-527.
- Hicks RM, Walters CL, El-Sebai I, El-Merzabani M, Gough TA (1976). Determination of nitrosamines in human urine: preliminary observations as the possible etiology for bladder cancer in association with chronic tract infections. *Proc. R. Soc. Med*. 70:413-416.
- Hill MJ (1988). *N*-nitroso compounds and human cancer, In: M. J. Hill (ed.), *Nitrosamine toxicology and microbiology*. Ellis Horwood, Chichester, United Kingdom. pp. 90-102.
- Ishikawa J, Xu HJ, Hu XS (1991). Inactivation of the retinoblastoma gene in human bladder and renal-cell carcinomas. *Cancer Res*. 51:5736-5743.
- Kantor AF, Hartge P, Hoover RN, Naragana AS, Sullivan JW, Fraumeni JF (1984). Urinary tract infection and risk of bladder cancer. *Am. J. Epidemiol*. 119:510-515.
- Kensler TW, Trush MA, Guyton KZ (1992). Free radicals as targets for cancer chemoprotection: prospects and problems. In: VE Steel, GD Stoner, CW Boone, and GJ Kelloff (eds.), *Cellular and Molecular Targets for Chemoprevention*. Ann Arbor, MI: CRC Press, pp. 173-191.
- Knowles MA, Williamson M (1993). Mutation of *H-ras* is infrequent in bladder cancer: confirmation by single-strand-conformation-polymorphism analysis, designed restriction-fragment-length polymorphisms, and direct sequencing. *Cancer Res*. 53:133-139.
- Koen KVV, Andre MD, Werner J, Eric AVM, Cornelis HH (2006). LactidNac- and LacNac-containing glycans induce granulomas in an *in vivo* model for schistosome egg-induced hepatic granuloma formation. *Glycobiology* 16(3):237-243.
- Kroft SH, Oyasu R (1994). Urinary bladder cancer: mechanism of development and progression. *Lab. Invest*. 71:158-174.
- Little NA, Wiener JS, Walther PJ, Paulson DF, Anderson EE (1993). Squamous cell carcinoma of the prostate: 2 cases of a rare malignancy and review of the literature. *J. Urol*. 149:137-139.
- Marietta MA (1988). Mammalian synthesis of nitrite, nitrate, nitric oxide and *N*-nitrosating agents. *Chem. Res. Toxicol*. pp. 249-257.
- Massoud MM, Saleh AI, Labib OH (1990). Studies on gastric bacterial growth and gastric pH in endemic schistosomal hepatosplenomegaly. *J. Egypt. Soc. Parasitol*. 20:559-563.
- Melzak J (1966). The incidence of bladder cancer in paraplegia. *Paraplegia*. 4:85-96.
- Miriam PR, Wagida AA, Amanda JW (1994). Inflammation, Chromosomal Instability and Cancer: The Schistosomiasis Model. *Cancer research (Suppl)*. 54: 1929-1933.
- Miyao N, Tsai TC, Lerner SP et al. (1993). Role of chromosome 9 in bladder cancer. *Cancer Res*. 53:4066-4070.
- Mostafa MH, Helmi S, Badawi AF, Tricker AR, Spiegelhalter B,

- Preussman R (1994). Nitrate, nitrite and volatile N-nitroso compounds in the urine of *Schistosoma mansoni* infected patients. *Carcinogenesis*. 15:619-625.
- Nelson WG, DeMarzo AM, Isaacs WB (2003). Prostate cancer. *New Engl. J. Med.* 349:366.
- Nordenstam GR, Ake Brandberg C, Oden AS, Svanborg Eden CM, Svanborn A (1986). Bacteriuria and mortality in an elderly population. *N. Engl. J. Med.* 314:1152-1156.
- Nurse P (1997). Regulation of the eukaryotic cell cycle. *Eur. J. Cancer.* 33:1002-1004.
- O'Brien PJ (1988). Radical formation during the peroxidase-catalyzed metabolism of carcinogens and xenobiotics: the reactivity of these radicals with GSH, DNA and unsaturated lipid. *Free Radical Biol. Med.* 4:216-226.
- Ottens H, Dickerson C (1972). Studies on the effects of bacteria on experimental schistosome infections in animals. *Trans. R. Soc. Trop. Med. Hyg.* 66:85-107.
- Parshad R, Price FM, Oshimura M (1992) Complementation of a DNA repair deficiency in six human tumor cell lines by chromosome 11. *Hum. Genet.* 88:524-528
- Radomski JL, Greenwald D, Hearn WL, Block NL, Woods FM (1978). Nitrosamine formation in bladder infections and its role in the etiology of bladder cancer. *J. Urol.* 120:48-50.
- Ronald JC, Stephen GE, Kumarasen C (1995). Schistosomiasis and prostate cancer. *Pathology.* 27(2):115-116.
- Shacter E, Beecham EJ, Covey JM, Kohn KW, Potter M (1988). Activated neutrophils induce prolonged DNA damage in neighboring cells. *Carcinogenesis (Lond).* 9: 2297-2304.
- Sidransky D, Von Eschenbach A, Tsai YC (1991). Identification of the *p53* gene mutations in bladder cancers and urine samples. *Science.* 252:70-709.
- Tamimi Y, Bringuier PP, Smit F, Bokhoven AV, Debruyne FMJ, Schalken JA (1996). Homozygous deletions of p16INK4 occur frequently in bilharziasis-associated bladder cancer. *Int. J. Cancer.* 68:183-187.
- Trush MA, Twerdok LE, Esterline RL (1990). Comparison of oxidant activities and the activation of benzo[a]pyrene-7,8-dihydrodiol by polymorphonuclear leukocytes from human, rat and mouse. *Xenobiotica.* 20: 925-932.
- Vilana R, Corachan M, Gascon J, Valls E, Bru C (1997). Schistosomiasis of male genital tract: Transrectal sonographic findings. *J. Urol.* 158(4):1491-1493.
- Warren W, Biggs PJ, El-Baz M, Ghoneim MA, Stratton MR, Venitt S (1995). Mutations in the *p53* gene in schistosomal bladder cancer: a study of 92 tumors from Egyptian patients and a comparison between mutational spectra from schistosomal and non-schistosomal urothelial tumors. *Carcinogenesis* 16:1181-1189.
- Weitberg AB (1989). Effect of combinations of antioxidants on phagocyte induced sister chromatid exchanges. *Mutagen. Res.* 224:1-4.
- Weitzman SA, Stessei TP (1981). Mutation caused by human phagocytes. *Science (Washington DC).* 212: 546-547.
- Weitzman SA, Weitberg AB, Clark EP, Stossel TP (1985). Phagocytes as carcinogens: malignant transformation produced by human neutrophils. *Science (Washington DC).* 227: 1231-1233
- Yamashina K, Miller BE, Heppner GH (1986). Macrophage-mediated induction of drug resistant variants in a mouse mammary tumor cell line. *Cancer Res.* 46:2396-2401.
- Yip I, Herber D, Aronson, W (1999). Nutrition and prostate cancer. *Urol Clin North Am.* 26:403-409.
- Young RH, Srigley JR, Amin MB (2000). Tumours of the prostate gland, seminal vesicles, male urethra, and penis. In *Atlas of Tumour Pathology*, 3rd series, fascicle 28. Washington DC: Armed Forces Institute of Pathology
- Zimmerman R, Cerutti P (1984). Active oxygen acts as a promoter of transformation in mouse embryo C3H/10T1/2/C18 fibroblasts. *Proc. Natl. Acad. Sci. USA.* 81:2085-2087.