

Full Length Research Paper

# Evaluation of oxytetracycline in the prevention of American foulbrood in bee colonies

Nada Plavša<sup>1</sup>, Dragica Stojanovi<sup>2</sup>, Igor Stojanov<sup>2</sup>, Nikola Puva a<sup>1\*</sup>, Vidica Stanacev<sup>1</sup> and Bosiljka Duricic<sup>3</sup>

<sup>1</sup>University of Novi Sad, Faculty of Agriculture, Department of Animal Science, Trg Dositeja Obradovi a 8, 21000 Novi Sad, Serbia.

<sup>2</sup>Scientific Veterinary Institute Novi Sad, Rumena ki put 20, 21000 Novi Sad, Serbia.

<sup>3</sup>University of Belgrade, Faculty of Veterinary medicine, Bulevar JA 18, Beograd, Serbia.

Accepted 13 January, 2021

In this paper, we presented the procedure of artificial infection of bee colonies with American Foulbrood by the spores of *Panibacillus larvae* (*P. larvae*). Bee colonies were treated with oxytetracycline that was applied in a patty and sugar syrup. The symptoms and the course of the disease within the bee colony were monitored. Our research included 20 bee colonies divided in three experimental and one control group. Every bee colony consisted of 2000 young worker bees and a young breeder queen. After laying of first eggs three experimental groups were infected with spore-suspension of *P. larvae* at concentration  $2 \times 10^9$  spore/ml. The development of the disease was monitored under the following experimental conditions: Experimental group I did not receive antimicrobial therapy, Groups II and III were given antibiotics in a sugar syrup and extender patty, respectively. In the first experimental group the first clinical signs were observed on day 25. while vegetative form of *P. larvae* was detected on day 12. Treatment with oxytetracycline in the second and third group delayed the manifest disease until day 47.

**Key words:** Bee colonies, American foulbrood, oxytetracycline.

## INTRODUCTION

American foulbrood is one of the most serious and destructive diseases of honeybee larvae that imperceptibly enter hives, spreading slowly and persistently, and finally resulting in the death of bee colony. In epizootiological sense American foulbrood is a typical chain-infection, one of the most widespread diseases of the bee brood (Uri et al., 2001). The causative agent is a bacterium *Panibacillus larvae* (Heyndrickx et al., 1996). It mostly affects the larvae of working bees, but it is contagious also for larvae of the drone and queen bees. Adult bees are not susceptible. *P. larvae* is apparent in two forms, the vegetative form (rods) and the form of spore, the latter one being infective for honeybees. Bee larvae less than 53 h old become infected orally, by swallowing *P. larvae* spores contained

in their feed. The older larvae are not susceptible. Spores are rarely detectable in larvae more than 53 h old. The spore germinates into the vegetative form immediately after entering the digestive tract of the larva, continuing to multiply until larval death. After the larva dies, new spores are formed. In only one cell with the dead larva as much as 2.5 milliard spores can be found (MSDTS OIE, 2000).

The number of spores required to produce the infection varies depending on other factors. Sturtevant and Revell (1953) produced infection using  $5 \times 10^7$  spores of *P. larvae*/g honey, while Hansen and Brodsgaard (1995) observed that feeding the bee colony with honey containing  $2 \times 10^9$  spore/g honey inevitably caused the outbreak of American foulbrood.

In the pathogenesis of the disease, it is well established that spore of *P. larvae* introduced into the organism of a young larva in opened brood does not immediately germinate into its vegetative form; however, it remains for a while in the intestine of the larva. After covering of cells,

\*Corresponding author. E-mail: [nikolapsto@yahoo.com](mailto:nikolapsto@yahoo.com).

at the sixth day of age, when the bees stopped feeding from the larva, the spore begins to germinate into its vegetative form, proliferating into the other organs via the hemolymph route (Goodwin and Eaton, 2002; Dobri et al., 2002). Changes in shape, color and consistency of larval body are obvious, finally resulting in larval death. The first signs of the disease are visible on the capping of the diseased cell, which becomes drawn down into the mouth of the cell, dark in color and perforated with tooth-edges. The dead larvae change gradually from a normal white color to the light yellow, even dark brown. They become loose, falling down to the bottom of the cell, and having thick, elastic, glue-like consistency. Larval remains can be drawn out into the thin threads or ropes. Gradually they dry to the black "scale" that holds tight to the base, which is difficult to remove (Bailey, 1981).

For the purpose of early diagnosing and detection of colonies infected with *P. larvae*, laboratory examination of honey samples is performed to confirm the presence of *P. larvae* spores (Hansen, 1984a). Hansen and Rasmusen (1986) discovered that honey could be contaminated with spores of *P. larvae* even six years before occurrence of the first clinical signs of the disease. Hornitzky and Clark (1993) recommend examination of honey samples as an effective way of detecting the causative agent, that is, determining prevalence of this microorganism on this particular area. For the final diagnosis of American foulbrood, besides clinical and pathoanatomic examination, laboratory diagnosis is necessary, that is, microscopy and bacteriological isolation of the causative agent in the suspected material (Lolin, 1985).

Specific therapy against American foulbrood is still lacking. New technologies resulted in development of number of eradication programs; however, destruction of all beehives is still the most practiced method worldwide (Shimanuki, 1990). During the last century several different attempts were made - in the 40's the sulphathiazole therapy was introduced, in the 50's the oxytetracycline therapy was launched, and in 90's resistance to oxytetracycline was proved (Shimanuki, 1997). This antimicrobial therapy can serve to suppress the spreading of the disease; however, spores of *P. larvae* cannot be killed or destroyed.

Kulin evi and Mla an (1987) confirmed that sugar/oil patty with prolonged oxytetracycline effect may be used in prevention of American foulbrood if applied in the initial stage of the disease. Investigation of Oldroyd et al.(1989) revealed that treating with oxytetracycline at concentration 1 g/colony could delay the symptoms of American foulbrood for 29 to 87 days, while in some of the colonies disease symptoms first occurred one year after therapy.

Our investigation was based on a common dilemma of the scientists worldwide: how many spores of *P. larvae* are needed to induce the disease, and how can antibiotics, applied in the feed, affect the course of the

disease.

## MATERIAL AND METHODS

### Bee colonies

For this investigation bee colonies free from American foulbrood were chosen.

Examination of the honey from the investigated hives revealed absence of *P. larvae* spores; hence no antimicrobial therapy was applied. "Pin-test" of the colony revealed high hygiene instinct in bees.

### Microorganisms

Artificial infection was performed using referent strains of *P. larvae* (5875 CAMP, Collection of Animal Pathogenic Microorganisms, Veterinary Research Institute, Czech Republic).

### Culture media

A special nutritive culture medium J-agar was used, consisting of: 20 g agar, 5 g tryptone, 15 g yeast extract, 3 g K<sub>2</sub>HPO<sub>4</sub>, 2 g glucose and one liter of demineralized water; blood agar (nutritive agar with 8% defibrinated sheep blood), nutritive medium with 2% NaCl, and nutritive medium with 5% NaCl, nutritive broth adjusted at 6.8 pH.

### Antibiotics

"Vazemicin R" ad. us. vet. was used, containing 55 mg oxytetracycline/1 g of powder for oral application (producer: Veterinary Institute, Zemun).

### Study subjects

This study included 20 bee colonies distributed in three experimental and one control group. Each colony consisted of about 2000 young worker bees and a young breeder queen. All experimental groups were infected with *P. larvae* spore suspension, at concentration 2x10<sup>9</sup> spore/ml. The course of the disease was monitored under the following conditions:

Experimental group I did not receive the oxytetracycline therapy. Experimental group II was given oxytetracycline at concentration 0.1 g/100 g of sugar syrup. The therapy was applied during 30 days, at 48-h-intervals (in the evening). Experimental group III received oxytetracycline in the extender patty at concentration 0.1 g/100 g. Clinical and laboratory examinations were performed on days 12, 25, 47 and 68. (Table 1)

## RESULTS

Microscopic examination performed on day 12 revealed the presence of vegetative rods of *P. larvae* in two colonies of the Experimental group I. Clinical examination on day 25 confirmed symptoms of American foulbrood in the same group, that is, overall comb appearance was "patchy" (Figure 2), cappings were dark in color (Figure 1) and larvae were colored chocolate-brown, elastic and

**Table 1.** Plan of the trial and situation in different phases.

Parameter	Experimental group (O-I)	Experimental group (O-II)	Experimental group (O-III)	Control group (K)
Number of hives	5	5	5	5
Size and power of the colony	2.000 bees + young breeder queen	2.000 bees + young breeder queen	2.000 bees + young breeder queen	2.000 bees + young breeder queen
Type of feed	sugar syrup 1:1	sugar syrup 1:1+ OTC	Extender patty + OTC	extender patty
Quantity of feed per colony	10 ml/da	10 ml sugar syrup +0,1 g OTC/at 2-day intervals	100 g extender patty + 0,1 g OTC/ at 5-6-day intervals	100 g extender patty at5-6-day intervals
<b>Situation on day 12</b>				
Control on day 12	No change in the comb appearance	No change in the comb appearance	No change in the comb appearance	No change in the comb appearance
Bacteriological control and finding	Bacterial rods in 2 colonies Spores of <i>P. larvae</i> in 3 colonies	Negative finding	negative finding	-
<b>Situation on day 25</b>				
Comb appearance	"patchy" comb, seals dark in Color, larvae of chocolate color and elastic	Compact ,convex cappings; in one colony cappings darker in color	Compact,convex capping	Compact, convex capping
Bacteriological control and finding	Bacterial rods in 2 colonies; spores of <i>P. larvae</i> in 3 colonies	Bacterial rods of <i>P. larvae</i> in the larvae in 2 colonies; spores of <i>P. larvae</i> in 1 colony	Negative finding	Negative finding for the examined sugar syrup
<b>Situation on day 47</b>				
Comb appearance	"Patchy" comb, seals dark in color, larvae of chocolate color and elastic	"Patchy" comb, seals dark in color, larvae of chocolate color and elastic	"Patchy" comb, seals dark in color, larvae of chocolate color and elastic in three colonies	Compact, convex cappings
Bacteriological control and finding	Spores of <i>P. larvae</i> in 2 colonies	Bacteria rods of <i>P.larvae</i> in 1 colony; spores of <i>P.larvae</i> in 3 colonies	Spores of <i>P.larvae</i> in 2 colonies, bacterial rods of <i>P.larvae</i> in 3 colonies	negative finding
<b>Situation on day 68</b>				
Comb appearance	-	"Patchy" comb, seals dark in color, larvae of chocolate color and elastic	"Patchy" comb, seals dark in color, larvae of chocolate color and elastic in two colonies	Compact, convex cappings
Bacteriological control and finding	-	Spores of <i>P. larvae</i> in the colony	Spores of <i>P.larvae</i> in both colonies	Negative finding

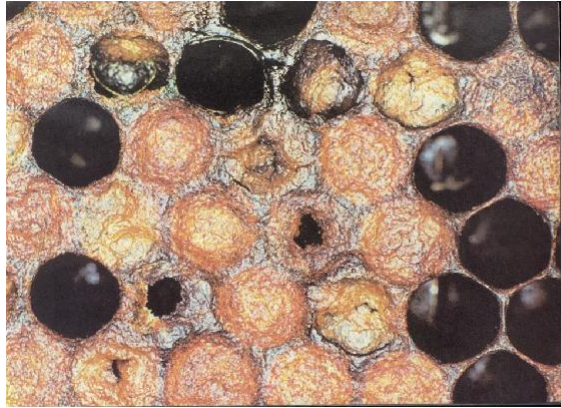

Figure 1. Characteristic appearance of the capping.

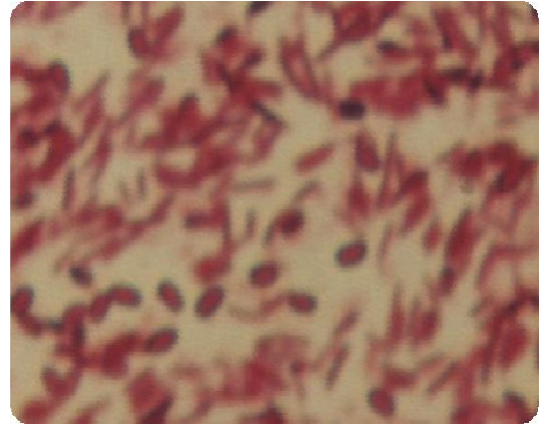


Figure 4. *Paenibacillus larvae* (spores and rods).




Figure 2. "Patchy" comb.



Figure 3. Rotten dead larva.

sticky (Figure 3). Bacteriological examination confirmed presence of spores and vegetative rods of *P.larvae* (Figure 4).

In the Experimental groups II and III clinical signs of the disease were not expected; however, bacteriological

examination revealed presence of bacterial rods in the Experimental group II.

Clinical and bacteriological examinations performed on day 47. revealed the American foulbrood in all three experimental groups. In the Experimental groups I and II two and three bee colonies were alive, respectively. In the Experimental group III all bee colonies were alive. In the control group no changes were observed, and all the colonies were alive.

On day 68. no more living colonies were observed in the Experimental group I, while only one living colony in the Experimental group II that exhibited pronounced clinical signs of the disease. In the Experimental group III we observed 2 living bee colonies with marked symptoms of the American Foulbrood and positive bacteriological findings.

## DISCUSSION

American foulbrood is a persistent, progressive, contagious disease of the honeybee brood. The infection appears in closed broods, and the outcome is always lethal. In our country the disease is widely spread and under Serbian health legislation it is notifiable and must be reported to the relevant authorities. In recent years antibiotics are increasingly applied in the "treatment and control" of the American foulbrood.

The susceptible larva is essential for the infection; however, development of the disease is determined by the number of *P. larvae* spores. The number of spores varies depending on different factors. Sturtevant and Revell (1953) induced artificial infection with American foulbrood with  $5 \times 10^7$  spores of *P. larvae*/g honey, while Hansen and Brodsgaard (1995) observed that feeding bee colonies honey containing  $2 \times 10^9$  spore/g honey necessarily caused the outbreak of the disease. Feeding of the larvae during the first six days, while the cell is still open, is very intensive. It is assumed that young larvae at this stage are visited and fed by feeding bees about

8.000 times, enlarging their weights 100 times during the first 3 days, and even 500 times within 6 days, which is the unique event in animal kingdom (Tomašec, 1955). Such a frequent feeding may easily introduce certain number of *P. larvae* spores into the larva. The least infective dose necessary to cause the infection is 35 spores for one-day-old larva (Woodrow, 1941); however, investigation performed next year by the same author revealed that only 10 spores are sufficient for one-day-old larva, and millions of them are needed to induce the infection in 4 to 5-days-old larvae. Brodsgaard (2003) indicated that the larvae are most susceptible between 24 and 28 h of age, with the lowest required infective dose being (ID<sub>50</sub>) 8.49 per one larva.

Our results indicated that in the Experimental group I, where artificial infection with *P. larvae* was performed, first clinical symptoms of American foulbrood and the first spores were detected after 25 days. In the Experimental group II that was treated with oxytetracycline in sugar syrup first signs of the disease were postponed until day 47. In the Experimental group III treated with oxytetracycline in extender patty, American foulbrood was clinically detected on day 47, but all the colonies were alive, and one of them survived even 68 days.

Similar results are reported by Oldroyd et al. (1989), who monitored the effects of oxytetracycline on 20 infected bee colonies. Colonies were housed in LR (eight framed) beehives and each colony was infected with  $2 \times 10^9$  spore per 1 ml of suspension.

It was discovered that 1 g oxytetracycline applied at the time of inoculation with *P. larvae* spores might postpone the disease in the hive (in two colonies) for 29 to 87 days, and in other colonies even up to one year. The same authors concluded that treatment with oxytetracycline in sugar syrup may delay American foulbrood for about one month, but application of oxytetracycline as prophylactic measure is not recommended. The results obtained in our study suggest that short period of delay is most probably due to the relatively small number of bees. Namely, our experiment included about 2000 bees, which is relatively small number in comparison to colonies in LR-beehives (extenders), with approximately 40.000 to 50.000 bees.

Similar results are reported by Baillay (1981), who observed that application of oxytetracycline in concentration of 0.25 to 0.40 g in 5 l sugar syrup per infected colony was not effective, while mixture of oxytetracycline, herbal fats and sugar, so-called "grease patty" was effective.

Application of antibiotics in apiary practice is of recent date. Chemotherapy was applied in some countries as early as in 40's of the 20th century, and sulphathiazole was considered a "miraculous remedy". Some years later, in the 50's, oxytetracycline was introduced. Numerous reports on research in this field were published (Lolin et al., 1987; Shimanuki, 1997; Allipi, 1999), and it was well established that oxytetracycline and other antibiotics did not affect the spores of *P. larvae*, impacting

only its vegetative form that is present at the beginning of the infection. This indicates that only continual antimicrobial therapy could protect bee colonies, which on the other hand, caused resistance of *P. larvae* to oxytetracycline. Reports of Shumanuki (1997) confirmed the resistance in Argentina, America and Canada. Chemical analyses of honey samples revealed presence of oxytetracycline residues that are highly harmful for human health (McKee, 2003; Plavša et al., 2003; Grujić 2003).

## REFERENCES

- Allipi A (1999). Comparative study of tylosin, erythromycin and oxytetracycline to control American Foulbrood of honeybee. *J. Apic. Res.*, 38( 3-4): 149-158.
- Bailey AS (1981). *Honey bee pathology*. Academic press, London, pp. 125-138.
- Brodsgaard C (2003). Control of American Foulbrood by the Shaking Method. *Apiacta*, 38: 140-145.
- Dobri, Vickovi D, Kulišić Z (2002). *Honeybee diseases*. Belgrade, pp. 32-136.
- uri i, Ilić Z, Bošnjak M, Plavša N (2001). Epizootična slika američke kuge pčelinjeg legla sa posebnim osvrtom na moguće greške u terapiji. *Zbornik plenarnih referata. I savetovanje o biologiji i zdravstvenoj zaštiti pčela*. Beograd, pp. 1-7.
- Goodwin M, Eaton C V (2002). Symptoms of American foulbrood. A Practical Manual for Beekeepers. Pest management Strategy – Elimination of American Foulbrood Without the use of Drugs. ([www.beekeeping.co.nz/disease](http://www.beekeeping.co.nz/disease)).
- Grujić S (2003). Model upravljanja kvalitetom prehrambenih proizvoda kao osnova za zaštitu geografskih oznaka porijekla meda. *Doktorska disertacija, Tehnološki fakultet, Banja Luka*, pp. 161-198.
- Hansen H (1984a). Methods for determining the presence of the foulbrood bacterium *Bacillus larvae* in honey. *Dan. J. Plant Soil Sci.*, 88: 325-328.
- Hansen H, Brodsgaard C (1995). Field trials with induced infection of *Bacillus larvae*. *Proceedings of the XXIV International Apiculture Congress of Apimondia, Lausanne*, pp. 166-171.
- Hansen H, Rasmussen B (1986). The investigation of honey from bee colonies for *Bacillus larvae*. *Tidsskrift for Planteavl*, 90: 81-86.
- Heyndrickx M, Vandemeulebroecke K, Hoste B, Janssen P, Kersters K, De Vos P, Logan NA, Ali N, Berkelay RC (1996). Reclassification of *Paenibacillus* (former *Bacillus*) *pulvificiens* (Nakamura, 1984), Ash et al. (1994). A later subjective synonym of *Paenibacillus* (former *Bacillus*) *larvae* (White 1906). *Int. J. Syst. Bacteriol.*, 46: 270-279.
- Hornitzky MAZ, Clark N (1993). Honey bee diseases. In *Australian Standard Diagnostic Techniques for Animal Diseases*. Commonwealth Scientific and Industrial Research. Victoria, Australia, pp. 3-7.
- Lolin (1985). *Bolesti pčela*. Beograd, pp. 11-17.
- Lolin, Ijušković B, uri i, la an V (1987). Ostojivost uzročnika američke kuge legla na antibiotike. *Zbornik radova 10. Kongres pčelara Jugoslavije*. Kragujevac, pp. 229-234.
- Manual of Standards for Diagnostic Tests and Vaccines (2000). American foulbrood. World Organisation for Animal Health ([www.oie.int](http://www.oie.int)).
- McKee B (2003). Prevention of Residues in Honey: A Future Perspective. *Apiacta*, pp. 38-173
- Oldroyd BP, Goodman RD, Hornitzky MAZ, Chandler D (1989). The effect on American Foulbrood of standard oxytetracycline hydrochloride treatments for the control of European foulbrood of honeybees (*Apis mellifera*). *Aus. J. Agric. Res.*, 40: 691-697.
- Plavša N, rabašić N, Bun i, Baltić Ž (2003). Procedura uzorkovanja i analiza kvaliteta meda na tržištu. *Zbornik plenarnih i naučnih radova – Kvalitet pčelinjih proizvoda i selekcija medonosne pčele*. Beograd, pp. 6-9.
- Shimanuki H (1990). Chapter Three: Bacteria in: Honey bee pests, Predators and Diseases. Second edition by R. Morse and R. Nowogrodski. Publish by Cornell University Press, pp. 28-47.

- Shimmanuki H (1997). Bacteria. In: Flottum, K.(Ed.), Honey bee Pests, Predators and Disease, third ed. Medina, Ohio, pp. 33-54.
- Sturtevant AP, Revell IL, (1953). Reduction of Bacillus larvae spores in liquid food of honey bees by action of the honey stopper, and its relation to the development of American foulbrood. J. Econ. Entomol., 46: 855-860.
- Woodrow AW (1941). Susceptibility of honey bee larvae to American foulbrood. Gleanings in Bee Culture, 69: 148-190.
- ulin evi , la an (1987). Preventive treatment of american foulbrood (Bacillus larvae) with sugar-oil antibiotic patties. Acta veterinaria, Beograd, 38(5-6): 267-272.
- mašec I (1955). Bolesti pčela. Zagreb, pp. 45-47.