

Full Length Research paper

Prevalence of different Nd:YAG Laser induced complication in patients with significant posterior capsule opacification and their correlation with time duration after standard cataract surgery

Aurangzeb Shaikh^{1*}, Faheemullah Shaikh², Jai Ram Adwani⁴ and Ziauddin Ahmed Shaikh³

¹Department of Ophthalmology, LUMHS Eye Hospital, Hyderabad, Pakistan.

²Department of Ophthalmology, LUMHS, Eye Hospital, Hyderabad, Pakistan.

³Department of Ophthalmology, Unit-I, Dow University of Health Science, and PCB Cell, Civil Hospital, Karachi, Pakistan.

⁴Department of Ophthalmology, PMC Hospital Nawabshah, Pakistan.

Accepted 16 August, 2020

To determine the prevalence of different types of eye complication due to Nd: YAG Laser posterior capsulotomy and its correlation with postoperative time duration following cataract surgery. Eyes underwent ND: YAG Laser posterior capsulotomy (on average 6 months to 3 years) after implantation of Intraocular lens (IOL) in posterior chamber of the eye. Determination of different types of Nd: YAG Laser induced complications in relation with postoperative time duration. We found a higher prevalence of post YAG laser AC reaction, raised intraocular pressure (IOP), IOL damage, vitreous reaction, macular and retinal damage. Nd: YAG Laser posterior capsulotomy is almost equally safe when performed after six months of cataract surgery.

Key words: Nd:YAG laser, posterior capsule opacification (PCO), intraocular lens (IOL), anterior chamber (AC), macular edema, vitreous hemorrhage, glaucoma.

INTRODUCTION

Posterior capsular opacification (PCO) is the most frequent post operative complication associated with decreased vision following modern cataract and intraocular lens (IOL) implant surgery (Nishi 1997). This Opacification develops in up to 50% of patients between two months and five years postoperatively (Green and Mc Donnell, 1985; Apple et al., 1992) In general older the patient lesser the incidence. It is 43.5% in infants and juveniles after three months (Oliver et al., 1990) and within two (2) years it approaches to 100% (Ionides et al., 1994). While the incidence in adults varies from 3.3 (Hussain and Durrani, 1995) 6 (Hussain, 1995) and up to 50% (Wilhelmus and Emery 1980; Kanski 2007). following cataract surgery depends upon the surgical technique (Meucci et al., 1991; Apple et al. 1985; Boulton and Saxby 2004) and type of IOL material used (Pande

et al 1995; Niazi et al 2006; Ahad et al., 2005).

Patients who have PCO with significantly reduced visual acuity need opening up of the posterior capsule in order to improve vision. The ways for posterior capsule-tomy are: Neodymium: Yttrium Aluminum Garnet (Nd: YAG) laser capsulotomy and Surgical capsulotomy (Boulton and Saxby 2004).

In 1980, Aron Rosa first reported the use of Nd: YAG laser to perform posterior capsulotomy (Kimiهارu, 1992) Nd: YAG laser works on the principle of photo disruption. It is the mechanical force, produced by disruption and emitting of electrons within the nuclei that causes break down of posterior capsule capsulotomy (Kimiهارu, 1992). Common techniques applied are cruciate pattern and racquet shaped (Shaikh, 1999) posterior capsulotomy. This procedure although safer, is not 100% free from risks.

The possible complications associated with this technique are Elevation of intraocular pressure, (Shaikh 1999; Channel and Beckman, 1984; Hasan et al., 1996; Latif and Aasi 1996; Skolnick et al., 2000; Hussain 1996;

*Corresponding author, E-mail: zebshaikh@hotmail.com. Tel: +92-21-2775445.

Ficker and Steele 1985; Khan et al., 2006; Panezai et al., 2004; Tayyab et al., 2004; Dawood et al 2007), Rupture of anterior vitreous phase (Shaikh, 1999; Latif and Aasi, 1996; Hussain, 1996 Khan et al., 2006; Panezai et al., 2004; Tayyab et al., 2004).

Damage of Intraocular lens (Khan et al., 2006; Panezai et al., 2004; Tayyab et al., 2004, Clayman et al., 1984; Riggins et al., 1995). Acute iritis (Arya et al., 2004), ant: uveitis is rare immediate complication (Shaikh, 1999; Hasan et al., 1996; Latif and Aasi, 1996; Skolnick et al., 2000; Dawood et al., 2007). Malignant glaucoma may rarely occur (Akhtar 1999). Cystoid macular edema (CME) is occasional complication of Nd: YAG laser posterior capsulotomy and is less common when capsulotomy is delayed for six (6) or more months after surgery (Kanski 2007; Shaikh 1999. Skolnick et al. 2000; Hussain 1996; Ficker and Steele 1985; Khan et al 2006; Panezai et al 2004; Tayyab et al 2004 ; Riggins et al. 1995), holes have also been reported ((Ficker and Steele 1985; Majeed et al 1998) Macular haemorrhage (Helbig et al., 1996), Vitreous haemorrhage (Sherrard and Kerr-Muir 1985), Corneal endothelial damage (Ficker and Steele 1985; Ranta et al., 2004). Rhegmatogenous retinal detachment is a rare complication and care should be taken in high risk patients like those having retinal detachment (RD) in the other eye or high myopes (Shaikh, 1999; Hasan et al., 1996; Latif and Aasi, 1996; Skolnick et al., 2000; Hussain, 1996; Banker and Freeman, 2001; Tetz et al., 1987). Chronic endophthalmitis is also a rare complication in which propionibacterium acnes, sequestered in the capsule gets an opportunity following YAG laser capsulotomy, to reach the vitreous (Maiman 1960).

Keeping all above facts in our mind we designed our study to note the prevalence of diggerent kind of complication with ND:YAG laser posterior capsulotomy.

Aim and objectives

To estimate the prevalence of different eye complication due to YAG laser capsulotomy and its correlation with postoperative time period after cataract surgery.

MATERIAL AND METHODS

After getting written informed consent from all patients who have had cataract surgery at least 6 month ago and their visual acuity was less than 6/12 with best available correction. All those patients were under went detailed eye examination (by filling special data recording form, which was developed for particular study) including Visual Acuity measurement (using standard Snell's vision chart placed at six meters), slit lamp examination (Top con model) with 90D (Volk) examination, Intraocular pressure measurement (Gold Man Tonometer). Posterior capsule and fungus examination was carried out after dilating the pupil with tropacamide 1% eye drops. Those who were full filling the selection criteria were under went YAG LASER posterior capsulotomy (LIGHT MED Nd: YAG laser manufactured by LIGHTMED CORPORATION mounted on a slit

lamp YAG laser machine) with Racket shape technique by applying contact lens. To reduce the chances of bias, all surgeries were carried out by Consultant Ophthalmologist. After Yag Laser Capsulotomy Data regarding to variable of interest were recorded on same day, after 1 week and finally after 4th week on data recording form.

Study design

This was a cohort study.

Setting: The study was conducted at Prevention and Control of Blindness Cell, Department of Ophthalmology, Unit-I, Civil Hospital, Karachi which is a one of tertiary Eye care centre in Sindh, this hospital drain referral from all over the province where facility for Yag laser capsulotomy is not available.

Sample size and duration of study: Keeping in our mind the prevalence of cataract and cataract surgical rate, we decided the sample frame of 314 adult patients, applying simple randomized strightified technique. The sample size was calculated by assuming 2% of prevalence of Posterior capsule Opacification (in adults have had their cataract surgery six months ago from the day of recruitment in this study) with 0.3% random sampling error precision and a design effect of 2.0% with 95% confident interval. This frame was further divided in to four sample units according to their post operative time period. The duration of this study was 6 months, starting from July to December, 2006.

Statistical method

The data analysis was performed with STATA version 9.0. Descriptive information for each of the variables is derived and distribution is assessed by simple tabulation, cross tabulation.

For the purpose of analysis we categorized the following definition used for analysis;

1. Visual activity category 1= Normal (6/12 or better), Category 2= Near Normal (<6/12-6/18), Category 3= Moderate visual impairment (<6/18to6/60), Category 4= Sever visual impairment (<6/60to3/60), Category 5= Blind (< 3/60)
2. AGE, Age group 1 = 30-39 years, Age group 2 = 40-49 years, Age group 3= 50-59 years, Age group 4 = 60-69 years, Age group 5 = 70-70+ years
3. Post operative duration category= 1 (6-12months), category=2 (13– 24 months), category=3 (25-36months), category=4 (37 months and above)
4. Demographic data. Rural=1, Urban=2.
5. Sex. Male=1, Female = 2
6. Intraocular pressure = Category 1= Normal (10-19 mmhg), Category 2= Abnormal (20 mmHg and above).

RESULTS

Demographically

There were total of 314 patients in our study. Females were predominant in our sample contributing 54.45% (171). Demographically there were 165 (52.54%) sample belongs to urban area and 149 (47.45%) to rural area. According to age groups 16 patients with significant posterior capsule opacification were in group 1, 30 in group 2, 128 in group 3, 110 in group 4 and 30 were in

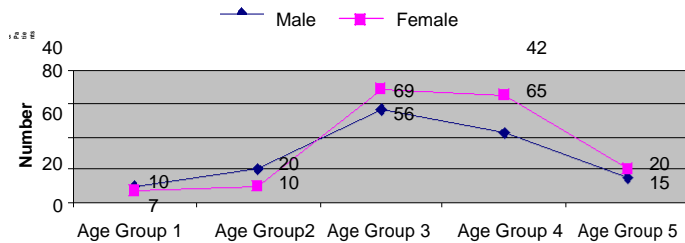


Figure 1. Prevalence of PCO in different age groups.

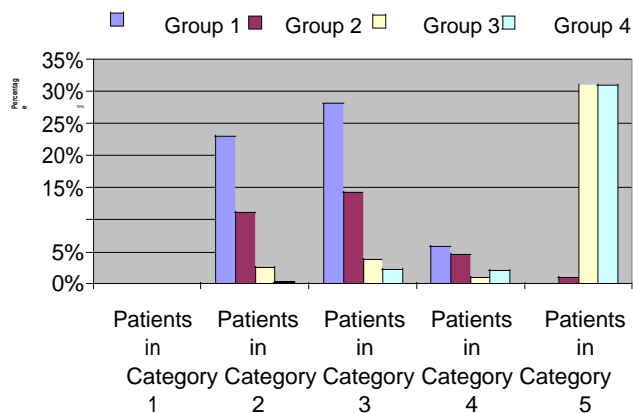


Figure 2. Visual status of patients in different V/A categories.

group 5. We found highest rate of PCO among age group 3 (128), than in group 4 (110), group 5(30), group 2 (30) and (16) in group 1 respectively (Figure 1). Most of the subjects in our study according to visual status fall into visual acuity category 3, than in category 2 (36.94%), category 4 (41.13%), category 5 (1.59%) and none in category 1 respectively. According to visual status most of our units fall in age group 3 (48.40%), than in category 2 (36.94%), category 4 (13%), category 5 (1.59%) and (0%) in group 1 respectively (Figure 2).

Complication in relation with post operative duration

We found higher prevalence of post YAG laser AC reaction regarding post operative duration group 1; 14 (11 on 1st post YAG visit and 3 were after 4 weeks) than in group 2; 8 (7 on 1st post YAG visit and 1 after 4 weeks), group 4; 4 (3 on 1st post YAG visit and 1 after 4 weeks) and 1 in group 3 after 4 weeks respectively.

Prevalence of raised intraocular pressure after YAG laser capsulotomy were higher in group 3 (16), (15) in group 1 and 4, and (10) in group 2.

We found prevalence of 7% for IOL damage during YAG laser posterior capsulotomy highest in group 3 than in group 1(4.49%), group 2(4.1%) and group 4 (1.27%). In our study we found very low prevalence for post-YAG laser for macular edema (0.3%), vitreous hemorrhage

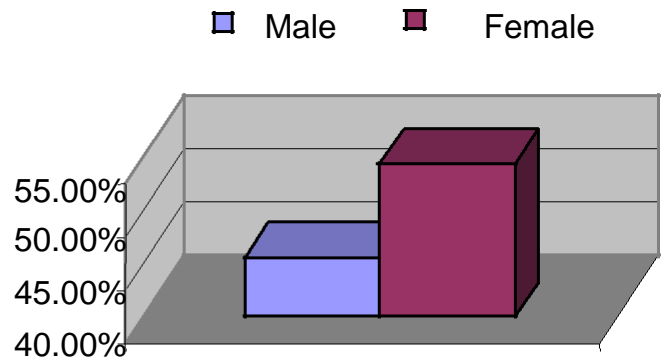


Figure 3. Prevalence of PCO in male and female.

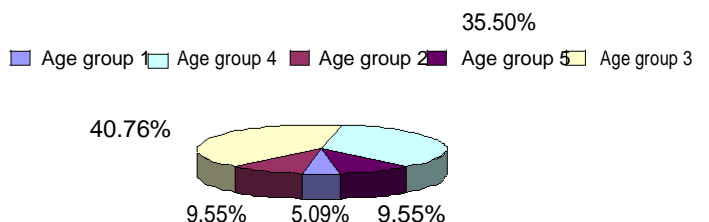


Figure 4. Percentage of patients in different age groups.

(0.63%) and (0%) for retinal damage.

DISCUSSION

PCO has not only medical but social and economic implications over the life of the patient, family and the society as a whole. Therefore, the techniques that alter the incidence of PCO are of considerable significance. The neodymium YAG laser has become popular non-invasive technique of creating a posterior capsulotomy in both pseudophakic and aphakic eyes.

There were total of 314 patients with significant posterior capsule opacification. Female ratio were higher than males, this was because of the higher prevalence of cataract among the females (Table 1 and Figure 3). Over all prevalence for posterior capsule opacification was higher among the urban patients (52.54%) as compared to patients belongs to rural area (Figure 4), this is because urban patients can easily get benefit from available services while because of distance and poverty it was very difficult for all rural patients to come in places like CHK to get benefit from the available service for posterior capsulotomy with Yag laser, we think this was the strong reason why sample frame from rural area have lower number of units. That does not mean that prevalence of PCO is lower in rural area.

In our study we found higher prevalence of PCO in age group 3 (40.76%) and lowest in group1 (5.09%) this is because of highest number of patients in group 3 and due to higher prevalence of PCO in younger units group 1 (Figure 5).

Table 1. Prevalence of PCO in different age groups according to sex.

AGE n = 314		Male (45.54%) n = 143	Female (54.45%) n = 171
Group 1	(30-39 years)	10	06
Group 2	(40-49 years)	20	10
Group 3	(50-59 years)	58	70
Group 4	(60-69 years)	43	67
Group 5	(70-70 plus)	10	20

Table 2. Showing the prevalence of A/C and Post Yag laser IOP.

Post operative duration after cataract surgery	Post YAG Laser AC reaction			Post YAG Laser IOP		
	Same day	After 1 week	After 4week	Same day	After 1 week	After 4 week
Group 1 n=178	00	11	03	12	03	00
Group 2 n=97	00	07	01	05	02	03
Group 3 n=24	00	00	01	09	06	01
Group 4 n=15	00	03	01	10	04	01

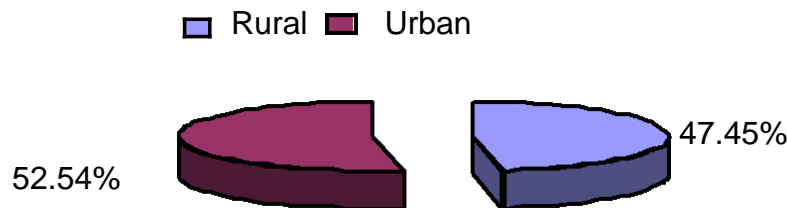


Figure 5. Demographically sample distribution

We also found transient rise in IOP on same day (average 3 mmHg) after YAG laser capsulotomy treatment but fortunately that was limited within normal range 15. But in the first follow-up week, there was a rise (maximum 6 mm Hg, higher than normal range) in IOP of all the three groups and higher incidence of sufferers was observed in Group-3 (34 %) as compared to other two groups (4 % in Group-1 and 15% in Group-2 patients) (Table 2). This did not indicate a time relationship of rise of IOP with IOL surgery and development of PCO but that group had higher number of elderly patients, who may have degenerating trabecular meshwork and also because of posterior capsular and cell debris, leading to the obstruction in the flow of aqueous humor. All of these patients were referred to Glaucoma Clinic for management and when they were examined on fourth week (one month after YAG capsulotomy) follow-up visit; their IOP was found to be at baseline level. Some authors have noted rise of IOP in more than three quarters of treated patients²⁴, Hussain MM in his study of 125 eyes treated by Nd: YAG laser capsulotomy found 25 - 30 mmHg rise in IOP in 1.6% cases (Hussain, 1996), whereas Hassan KS and associates found average 6 mmHg rise in IOP in 37.9% aphakic eyes out of 29 eyes

and 16.07% in pseudophakic eyes out of 57 eyes (Hasan et al., 1996). In our study, the incidence of rise in IOP is low because all patients had posterior chamber IOL implantation, they were selected with normal IOP and we used very low energy levels.

In our study, on 1st post YAG visit we found higher prevalence of A/C reaction in all groups in relation to post operative time period (Table 2). Highest incidence of A/C reaction in Group-I patients may be due to the fact that younger patients show strong immune responses to the radiation injury and higher number of patients in Group-III may be due to degenerating trabecular meshwork in elderly, leading to late clearance of inflammatory debris. In comparison with other study conducted for same reason, we noted very low prevalence of A/C reaction in our study 19 may be because we avoided laser treatment in early post-operative days and used low energy levels.

In our study, 8 (4.49%) in Group- 1, 4 (4.1) in Group-2, 6(25%) in Group-3 and 03(75%) in group 4 patients had inadvertent IOL pitting (Table 3). In none of these cases the pitting accounted for significant IOL damage leading to visual impairment. This was because the area of laser application was away from the axial area (Shaikh, 1999). Overall higher incidence of IOL damage and particularly

Table 3. Showing the prevalence of IOL and retinal damage

Post operative time period	Post YAG Laser IOL damage (%)	Post YAG Laser retinal damage
Group 1 (n= 178)	08 (4.49)	00
Group 2 (n= 97)	04 (4.1)	00
Group 3 (n= 24)	06 (25)	00
Group 4 (n= 15)	03 (75)	00

Table 4. Showing the prevalence of variable of interest.

Post operative time period n=314	Post YAG Laser macular edema			Post YAG Laser vitreous hemorrhage		
	Same day	1 week	3 week	Same day	1 week	3 week
Group 1 n=178	00	00	00	00	00	00
Group 2 n=97	00	00	00	00	00	00
Group 3 n=24	00	00	00	00	01 (4.1%)	00
Group 4 n=15	00	00	01 (6.66%)	00	01 (6.66%)	01 (6.66%)

in Group-3 & 4, may be due to elderly patients, which may be due to the reason that elderly patients feel greater difficulty in stabilizing their head during the procedure for longer period of time. Another reason could be that Civil Hospital Karachi is a teaching institution, where surgeons performing YAG capsulotomy ranged from residents / trainees to senior surgeons, so there could be higher incidence of IOL pitting in patients treated by trainees. Hassan KS and associates have noted high incidence of IOL pitting 19.8% cases in a study of 86 eyes (Hasan et al., 1996), and Khan MY and associates have noted 22.4% incidence of IOL damage in their study (Khan et al., 2006). Also retro focusing of laser aiming beam reduces the risk of IOL pitting (Ficker and Steele, 1985).

We noted the prevalence of cystoid macular edema (CME) (Table 4) in 1 patient in Group-4 only or overall 0.31% (1 in 314 patients) but that was only diagnosed with 90D lens on slit lamp examination. We found very low prevalence of macular edema in our study as compared with other studies (Hussain, 1996 Khan et al., 2006; Dawood et al., 2007) may be because we don't confirm cystoid macular edema by standard diagnostic tool like Fundus fluorence angiography and Optical coherence angiography OCT (Kanski, 2007).

This low prevalence may also be because we select all patients with PCO after 6 months of surgery that is enough time for the full recovery of leaking paramacular capillaries that lead to formation of cystoid macular edema (Lindstrom, 1987).

We could document vitreous haze (Table 4) in one (01 or 1%) patient in Group- III (overall 1 in 300 or 0.33% patient only. It remained there, on follow-up after one week and thereafter three weeks (one month after YAG capsulotomy). We found 0% prevalence of Retinal damage due to Yag Laser Capsulotomy (Table 4).

If we look to and consider the results of our study in all

the four groups, it can be said that the complications occurring after Nd: YAG laser capsulotomy, are not related to the time interval between cataract surgery and development of PCO. The higher incidence of raised IOP occurred in Group-3, comprising elderly patients, who had larger interval between IOL surgery and development of PCO as compared to other two groups. The higher incidence of A/C reaction occurred in Group-1, comprising comparatively younger patients, who had smaller interval between IOL surgery and development of PCO as compared to other two groups. The higher incidence of IOL damage occurred in Group-3, comprising elderly patients, who had larger interval between IOL surgery and development of PCO as compared to other two groups. The incidence of CME and vitreous haze occurred in Group-3 patients, who had larger interval between IOL surgery and development of PCO as compared to other two groups, which showed none.

There are certain complications produced by the physical effects (that is, radiation injury) of YAG laser, like sterile inflammatory A/C reaction. Other complications can not be directly blamed on YAG laser but they occur due to other factors including the experience of operating surgeon, patients compliance of instructions regarding stability of head and no movements of the eyes during the procedure and physical state of trabecular meshwork, which is related to clearance of inflammatory and other debris produced by radiation injury and cutting of posterior capsule.

Conclusion

We can conclude that even though Nd: YAG capsulotomy can not be said to be 100% free from the risk of complications like other surgical procedures, it is almost safe when performed after six months of the cataract surgery.

ACKNOWLEDGEMENTS

I am very thankful to my Professor Dr. Ziauddin Ahmed Shaikh, Dr. Jai, and Dr. Fahimullah Shaikh without their helping hand; I may not be able to complete this paper. I am also thankful to the staff of Prevention and Control of Blindness cell for their support and cooperation.

REFERENCES

- Ahad MA, Qamar MR, Hindi SK, Kid MN (2005). Effect of anterior capsular polishing on the incidence of YAG capsulotomy. *Ann King Edward Med. Coll. Sept.* 11(3): 273-276.
- Akhtar MS (1999) YAG laser capsulotomy in eyes without IOL's. *Pak. J. Ophthalmol.* 5 (2): 43-44.
- Apple D, Reidy J, Googe J (1985). A comparison of ciliary sulcus and capsular bag fixation of PC IOL. *J. Am. Intraocul. Implant Soc.* 11: 44-63.
- Apple DJ, Solomon KD, Tetz MR, Assia EI, Holland EY, Legler UF (1992). Posterior capsule opacification. *Surv. Ophthalmol. Sept-Oct.,* 37(2): 73 -116.
- Arya SK, Sonika, Kochhar S, Kumar S, Kang M, Sood S (2004). Malignant glaucoma as a complication of Nd: YAG laser posterior capsulotomy. *Ophthalmic Surg. Lasers Imaging.* May-Jun., 35: 248-50.
- Banker AS, Freeman WR (2001). Retinal Detachment. *Ophthalmol. Clin. North Am. Dec.,* 14(4): 695-704.
- Boulton M, Saxby LA (2004). Secondary cataract. In Yanoff M, Duker JS (Editors). *Ophthalmology.* St. Louis, Missouri. Mosby Inc. 34: 265-268.
- Channel MM, Beckman H (1984). IOP changes after Nd: YAG laser posterior capsulotomy. *Arch. Ophthalmol.,* 102: 1024.
- Clayman HM, Karenburg FG, Parel JM (1984). Intraocular lens damage from Nd: YAG laser. *Am. J. Ophthalmol.* 16: 551-553, 556.
- Dawood Z, Mirza SA, Qadeer A (2007). Review of 560 cases of YAG laser capsulotomy. *J. Liaquat. Univ. Med. Health Sci.* 6(1): 3-7.
- Ficker LA, Steele AD (1985). Complication of Nd: YAG laser post capsulotomy. *Trans. Ophthalmol. Soc. U.K.* 104: 529-532.
- Green WR, Mc Donnell PJ (1985). Opacification of posterior capsule. *Trans. Ophthalmol. Soc. U.K.* 104: 727-39.
- Hasan KS, Adhi MI, Aziz M, Shah N, Farooqui M (1996). YAG laser posterior capsulotomy: experience at Civil Hospital Karachi. *Pak. J. Ophthalmol.* 12 (1): 3-7.
- Helbig H, Keller U, Bofmelfeld N, Foerster MH (1996). Cataract surgery and YAG laser capsulotomy following vitrectomy for diabetic retinopathy. *Ger. J. Ophthalmol.* 5(6): 408-414.
- Hussain M, Durrani J (1995). Intra ocular lens implantation. A review of 2527 eyes. *Pak. J. Ophthalmol.* 11: 103-108.
- Hussain MM(1996). Complication after Nd:YAG laser capsulotomy. *Pak J. Ophthalmol.* 12 (1): 13-15.
- Hussain MM (1995). Incidence of PCO following ECCE. *Pak. J. Ophthalmol.* 11: 77-78.
- Ionides A, Dowler JG, Hykin PG, Rosen PH, Hamilton AM (1994). Posterior capsular opacification following diabetic intracapsular cataract extraction. *Eye* 8 (5): 525-537.
- Kanski JJ (2007). Acquired macular disorders and related conditions. In Kanski JJ (editor) *Clinical Ophthalmology. A systemic approach.* 6th ed. London. Butterworth Heinemann pp.627-261.
- Kanski JJ Lens (2007). In Kanski JJ (editor) *Clinical Ophthalmology. A systemic approach.* 6th ed. London. Butterworth Heinemann, pp.337-367.
- Khan MY, Jan S, Khan MN, Khan S, Kundi N (2006). Visual outcome after Nd: YAG capsulotomy in posterior capsular opacification. *Pak. J. Ophthalmol.* 22(2): 87-91.
- Kimiharu N (1992). *Ophthalmic laser therapy.* Iga Ku Shoin Tokyo pp. 103 – 110.
- Latif E, Aasi NA (1996). Treatment of postoperative pupillary membrane with Nd: YAG laser (Study of 72 cases treated at Bahawal Victoria Hospital, Bahawalpur). *Pak. J. Ophthalmol.* 12 (1): 8 -12.
- Lindstrom R (1987). YAG Laser Posterior Capsulotomy. *Ocular Surg. N.* 7: 18.
- Maiman TH (1960). Stimulated optical radiation in ruby. *Nature* 187: 493.
- Majeed A, Bungash T, Muzzafer W, Durrani O (1998). Macular haemorrhage: An unusual complication of Nd: YAG laser capsulotomy. *Pak. J. Ophthalmol.* 14(3): 118-120.
- Meucci G, Esente S, Esente I (1991). Anterior capsule cleaning with an ultrasound irrigating scratcher. *J. Cat. Ref. Surg.* 17: 75-79.
- Niaz MK, Hanif MK, Khan HA, Yaqub MA (2006). YAG capsulotomy rates following implantation of PMMA and Acrylic intraocular lenses. *Professional Med. J.* 13 (4): 538-542.
- Nishi O (1997). After cataract the last big hurdle in Cataract Surgery. *Int. J. Ophthalmol.* 2: 9-11.
- Oliver M, Milstein A, Pollack A (1990). Posterior chamber lens implantation in infants and juveniles. *Eur. J. Implant Ref. Surg.* 2: 309-314.
- Pande M, Ursell PG, Spalton DJ (1995). Posterior Capsular Opacification with PMMA, Silicon and Acrisof intraocular lenses: a prospective randomized clinical trial. *Invest Ophthalmol. Vis. Sci.* 36 (suppl.): 397.
- Panezai MN, Shahwani MA, Hameed K (2004). Posterior capsular opacification (PCO) and Nd: YAG laser capsulotomy in Helper's Eye Hospital Quetta. *Pak. J. Ophthalmol.* 20: 115-8.
- Ranta P, Tommila P, Kivela T (2004). Retinal breaks and detachment after Neodymium YAG laser posterior capsulotomy: five year incidence in a prospective Cohort. *J. Cat. Ref. Surg.* 30: 58-66.
- Riggins J, Pedrotti LS, Keates RH (1983). Evaluation of the Nd: YAG laser for treatment of ocular opacities. *Ophthalmic Surg.* 14: 675.
- Awan KJ (1995). Acute iritis following Nd: YAG laser posterior capsulotomy. *Ophthalmol.* 11(3): 90.
- Shaikh ZA (1999). Racquet shaped posterior capsulotomy using Nd: YAG laser. *Pak. J. Ophthalmol.* 15: 10 -14.
- Sherrard ES, Kerr-Muir MG (1985). Damage of corneal endothelium by Q-switched Nd: YAG laser posterior capsulotomy. *Trans. Ophthalmol. Soc. U.K.* 104: 524-528.
- Skolnick KA, Perlman JI, Long DM, Kernan JM (2000). Neodymium YAG laser posterior capsulotomies performed by Residents at a Veterans Administration Hospital. *J. Cat. Ref. Surg.* 26(4): 597-601.
- Tayyab AA, Sahi TN, Ajmal M, Zafar Ullah M, Javed MA (2004). Frequency of posterior capsular opacification following PMMA vs silicone posterior chamber IOL implantation with phacoemulsification. *Pak. J. Ophthalmol.* 20 (3): 96-69.
- Tetz MR, Apple DJ, Price FW Jr., Piest KL, Kincaid MC (1987). Bath PE. A newly described complication of Nd: YAG laser capsulotomy: Exacerbation of an intra ocular infection. *Arch. Ophthalmol.* 105 (10): 1324-1325.
- Wilhelmus KR, Emery JM (1980). PCO following phacoemulsification. *Ophthalmic Surg.* 11: 264-267.
- Winslow RL, Taylor BC (1985). Retinal complications following YAG laser capsulotomy. *Ophthalmol.* 92: 785-789.